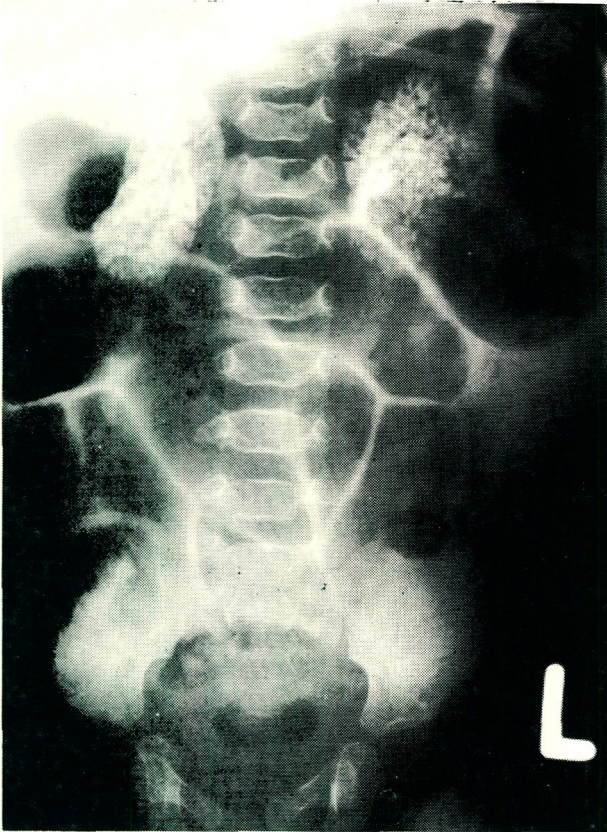

MEDICAL QUIZ

Prepared by
Akbar Mohsin Mohammad* and
Najeeb S. Jamsheer**

CASE 1

This chest/abdomen X-ray was taken of an infant who ultimately died.



Question 1. What are the abnormal findings in this X-ray?

Question 2. What organ(s) is/are involved?

Question 3. What is the differential diagnosis?

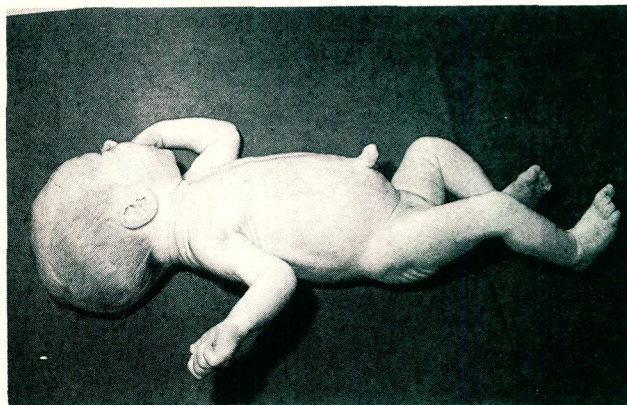
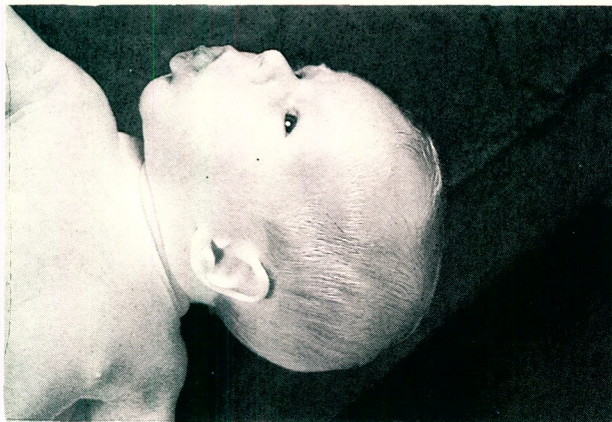Question 4. What is the definitive diagnosis?

*Chairman,
Paediatric Department,
Salmaniya Medical Centre.

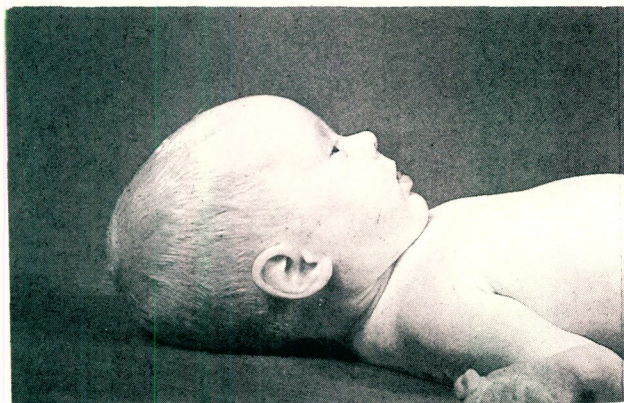
**Chairman,
Radiology Dept,
Salmaniya Medical Centre.

CASE 2

A two month old infant.



Before treatment



After treatment

Question 1. What is your diagnosis?

Question 2. What was the treatment?

Anyone interested in presenting a quiz for publication should contact Dr. Akbar Mohsin Mohammad on Tel.: 250662.

Answers on Page 108.