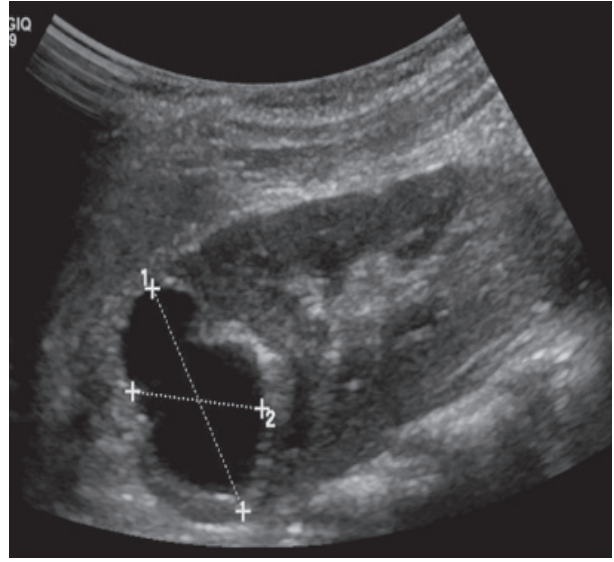
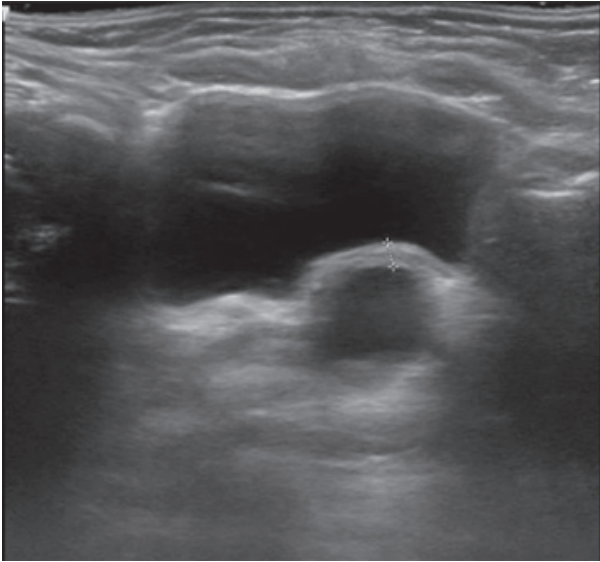


Medical Quiz

Saeed Alhindi, MD, CABS, FRCSI*

A two-year-old female presented with a history of lower abdominal pain associated with fever and vomiting. The patient underwent radiological investigations. Look at the figures below and answer the following questions:



Q.1: Describe the findings in the figures.

Q.2: What is the most likely diagnosis?

Q.3: What is the initial management of this condition?

Answers on page137

* Consultant Pediatric Surgeon
Department of Pediatric Surgery
Salmaniya Medical Complex
Assistant Professor, Arabian Gulf University
P.O. Box 12
Kingdom of Bahrain
E-mail: sjalhindi@gmail.com; sjalhindi@yahoo.com