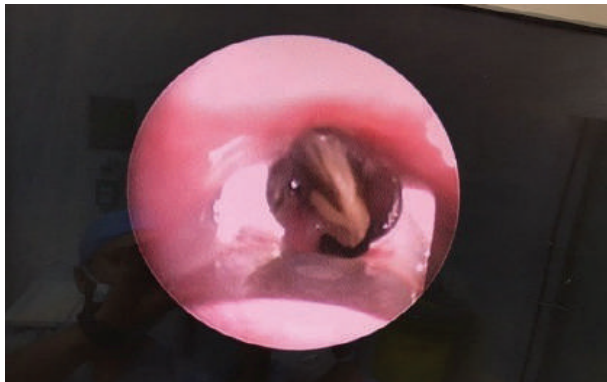


Spontaneous Assisted Ventilation in the Extraction of a Seed in the Left Main Bronchus

Hassan Alansari, MBBCh, BAO* Yomna Elsheikh Ahmed, MBBCh, BAO** Abdulla Alkhalfan, MBBCh, BAO***
Hiba Al Reefy, MBBCh, DOHNS, FRCS (ORL-HNS)**** Keith Johnston, MBchB, FRCA*****

We report a six-year-old Egyptian male who had aspirated a sunflower seed in his airway. The seed was removed using a fiberoptic camera and long forceps while he was ventilated using the SAV method.



Author Contribution: All authors share equal effort contribution towards (1) substantial contributions to conception and design, acquisition, analysis and interpretation of data; (2) drafting the article and revising it critically for important intellectual content; and (3) final approval of the manuscript version to be published. Yes.

Potential Conflicts of Interest: None.

Competing Interest: None.

Sponsorship: None.

Acceptance Date: 6 February 2018