

Education-Family Physician Corner

Recurrent Chalazia Revealing an Ocular Rosacea in a Child

Wael Wagih, FRCSEd, PhD, MCs* Abdulla Almoosa, MD** Houyem B. Ayed, MD***

Chalazion in childhood and early adolescence is a common condition frequently seen in ophthalmic practice. The diagnosis is usually straightforward and surgical treatment by incision and curettage is frequently advised. Emphasis on the cause of this common pathology is often overlooked.

We present a case of recurrent chalazion in a 14-year-old female, which was associated with ocular rosacea. Ophthalmologic examination confirmed recurrence of chalazion, severe bilateral blepharitis and involvement of cornea with the presence of infiltration and neovascularization.

The patient was treated with doxycycline 100 mg once a day and topical steroid treatment. The follow-up was marked by partial remission of the disease with frequent relapses. Topical azithromycin 1.5% was used and the ocular inflammation was quickly resolved. One year after discontinuation of local therapy with azithromycin, the patient remained recurrence free.

Bahrain Med Bull 2017; 39(3): 169 - 171

Rosacea is a common chronic skin disease, which has different manifestations. The disease targets pilosebaceous glands and small blood vessels involving the mid-facial area. It usually affects adults but could be seen in childhood¹.

Although it is a skin disorder, ocular involvement may reach up to 58% to 72%; it may cause eyelid or ocular surface inflammation with sight-threatening complications in approximately one-third of the patients¹.

The aim of this report is to present a case of acne rosacea in a child with ophthalmic involvement.

THE CASE

A fourteen-year-old Bahraini female presented with bilateral blepharoconjunctivitis, photophobia and blurred vision in the left eye. She was previously operated for bilateral recurrent chalazion under general anesthesia and was treated with topical skin treatment.

Examination of the face showed papules and pustules on both cheeks and central forehead, see figure 1 (A). Best corrected visual acuity was 6/7.5 OD and 6/9 OS, respectively. The patient was having inflamed chalazion in her right upper eyelid, with diffuse conjunctival and ciliary congestion in her left eye, see figure 1 (B and C). Slit lamp examination revealed severe blepharitis, meibomitis with flakes around lashes in all four lids, see figure 2. There was superficial punctate keratitis in both eyes with pannus in the left eye and corneal infiltrates, see figure 3.

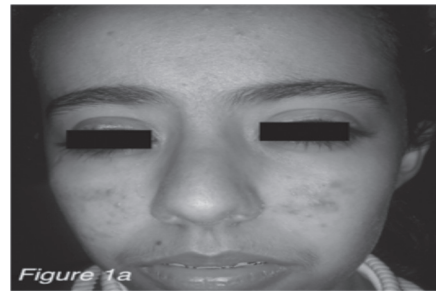

Figure 1 (A): Papules and Pustules on Both Cheeks and Central Forehead

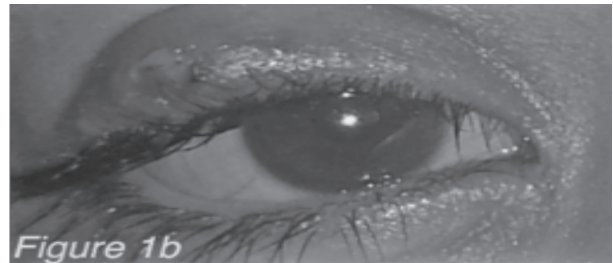


Figure 1 (B): Right Eye Inflamed Chalazion Fistulized to Upper Lid Skin

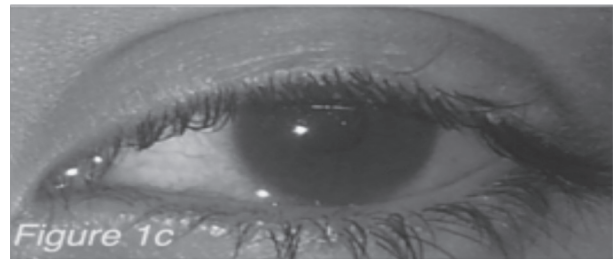


Figure 1 (C): Left Eye Diffuse Conjunctival Redness and Increased Lacrimal Film

* Consultant Ophthalmologist and Head of Department
** Senior House Officer
*** Registrar
Department of Ophthalmology
King Hamad University Hospital
The Kingdom of Bahrain
E-mail: wael.wagih@khu.org.bh

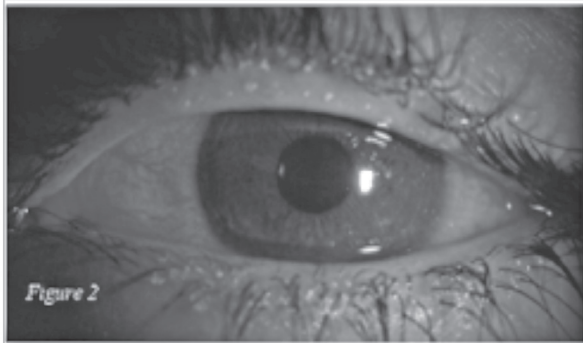


Figure 2: Right Eye Severe Blepharitis with Meibomitis and Flakes around Eyelashes

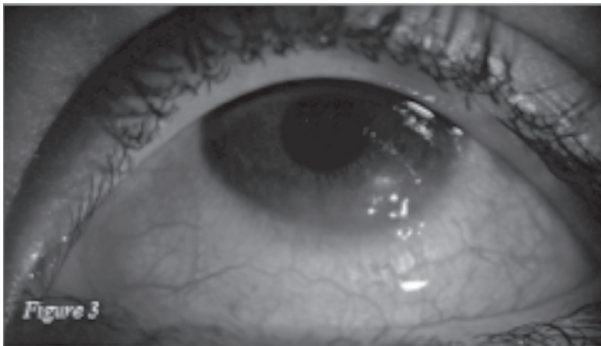


Figure 3: Left Eye Corneal Infiltrate at 5 O'clock Position with Neovascularization

The patient was started on systemic doxycycline 100 mg/day with topical lubricants hourly and steroids TID. Parents were advised to follow proper lid hygiene with warm compresses and massage of the lids after cleaning the eyelashes thoroughly twice daily.

The patient was not compliant with treatment, which resulted in multiple remissions and exacerbations of blepharitis, meibomitis and recurrence of chalazion. Therefore, topical azithromycin 1.5% was used; she received three courses per month for two consecutive months followed by two courses per month for an additional two months. In each course, she received one drop every six hours for three consecutive days. The disease was controlled, her vision improved to 6/6, chalazion resolved without surgery, blepharitis and meibomitis were cured, the conjunctival redness was rapidly resolved, but corneal infiltrates took more time to resolve. Over the last year, she has been doing well on topical lubrication and lid hygiene, see figures 4 (A and B).

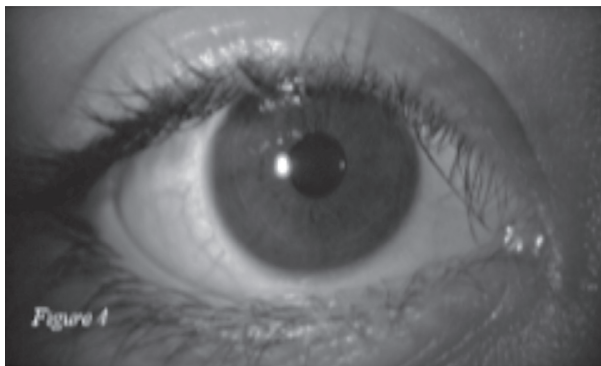


Figure 4 (A)

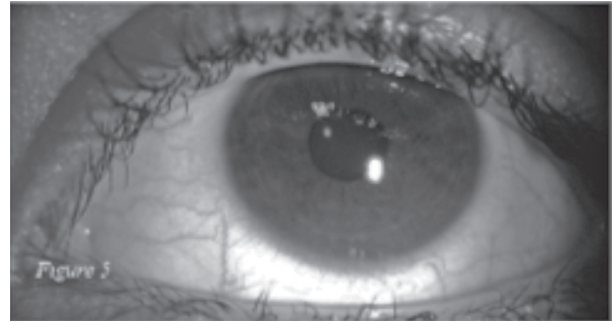


Figure 4 (B)
Figure 4 (A and B): Right and Left Eyes after 4 Months of Azithromycin Treatment Showing Healed Chalazion, Resolved Blepharitis, Clear Corneas with Disappearance of Corneal Infiltration and Neovascularization

DISCUSSION

A recent study on the epidemiology of rosacea revealed an incidence rate of 1.65/1,000 person/year, as diagnosed by general practitioners².

Childhood rosacea is usually underestimated and often considered to be rare as dermatological signs are usually hidden or present in mild form^{1,3-6}.

Pathophysiologic mechanisms of cutaneous and ocular rosacea remain unclear; however, several studies confirm the vascular and inflammatory nature of the disease^{1,4}.

Predisposing factors of ocular rosacea include climate factors, abnormal pilosebaceous glands. Several microorganisms namely *Helicobacter pylori*, *Demodex folliculorum*, and *Staphylococcus epidermidis* have been implicated in the exacerbation of the disease; however, their role remains controversial¹.

In ocular rosacea, primitive meibomian dysfunction will produce viscous meibum, rich in free fatty acids which irritate the corneal epithelium and the conjunctiva and destabilize the lacrimal film. Infection of lid margin with staphylococcus leads to keratoconjunctivitis secondary to T-cell activation⁶.

Pediatric rosacea clinical features mimic those seen in adults. However, the skin changes are usually subtle in children, thus, making the diagnosis more challenging. It has been reported that 55% of children would develop ocular changes before dermatological findings start to appear⁵. Rosacea is characterized by central facial erythema, symmetric flushing, inflammatory lesions (papules and pustules), telangiectasias and phymatous changes (thickened skin and large pores)^{1,5,7}.

Approximately 60% of the patients with rosacea could have ocular involvement. Symptoms could include excess tearing, itchy eyes, foreign body sensation and photophobia. Visual impairment occurs secondary to corneal involvement; both eyes are usually affected^{1,5}. Rosacea typically manifests with meibomian dysfunction; that results in recurrent chalazion, severe meibomitis, dry eyes and chronic conjunctivitis in children. The cornea is involved in approximately 33% of patients; it commonly presents as superficial punctate keratitis

in the lower third of the cornea, perilimbal neovascularization with subepithelial infiltrates along the advancing vascular border^{1,5}. That was seen in our patient left eye, see figure 3. The corneal lesions, if left untreated, may lead to ulceration and even perforation. Corneal scarring and opacification are possible complications¹.

The differential diagnosis of ocular rosacea may include Staphylococcal and seborrheic blepharconjunctivitis¹.

The first line of management is conservative measures including lid hygiene using warm compression with a baby shampoo wash. Although it is difficult to maintain this habit in children, the parents play an important role in reinforcing these measures^{1,4,6,8}. Blephasteam is a warming goggles designed specifically to produce a moist heat which emulsifies meibum^{8,9}.

Azithromycin 1.5% eye drops are an effective treatment in non-severe forms of ocular rosacea with phlyctenular blepharokeratoconjunctivitis. Topical erythromycin ointment may also be used on eyelid margins^{1,5}.

Systemic treatment must be prescribed to control ocular rosacea in pediatric group and adults, but tetracycline should not be prescribed to patients younger than seven years because of dental staining and impairment of bone growth. In these cases, erythromycin or azithromycin (20 mg/kg/day) is preferable. Systemic metronidazole (20 mg/kg/day) is also a good alternative^{4,5}. Daily doxycycline (100 mg orally) is a favorable choice to be used in older children as it is well tolerated compared to tetracycline. A course of 6 to 12 weeks is very helpful in the treatment of ocular rosacea among children⁷. The FDA approved 40 mg doxycycline for the treatment of rosacea daily. Persistent chalazion may require surgical treatment⁷.

A low dose of topical steroid drops may be necessary to control surface inflammation and treat phlyctenular blepharokeratoconjunctivitis and corneal neovascularization. Relapse occurs at the end of treatment in up to 40% of cases. In the case of steroid dependence, Cyclosporine drops 0.5% or 2% could be prescribed to control inflammation^{1,6,10}.

CONCLUSION

Lids hygiene is an essential part of management of rosacea in children. Parents should be educated for compliance. Topical azithromycin is safe and efficient in non-severe ocular rosacea. Systemic treatment is beneficial for ocular and cutaneous manifestations.

Author Contribution: All authors share equal effort contribution towards (1) substantial contribution to conception and design, acquisition, analysis and interpretation of data; (2) drafting the article and revising it critically for important intellectual content; and (3) final approval of manuscript version to be published. Yes.

Potential Conflicts of Interest: None.

Competing Interest: None.

Sponsorship: None.

Acceptance Date: 20 July 2017.

Ethical Approval: Approved by the Research and Ethics Committee, King Hamad University Hospital, Bahrain.

REFERENCES

1. Vieira AC, Höfling-Lima AL, Mannis MJ, et al. Ocular Rosacea--A Review. *Arq Bras Oftalmol* 2012; 75(5):363-9.
2. Spoenclin J, Voegel JJ, Jick SS, et al. A Study on the Epidemiology of Rosacea in the U.K. *Br J Dermatol* 2012; 167(3):598-605.
3. Potz-Biedermann C, Mehra T, Deuter C, et al. Ophthalmic Rosacea: Case Report in a Child and Treatment Recommendations. *Pediatr Dermatol* 2015; 32(4):522-5.
4. Léoni S, Mesplé N, Aitali F, et al. Metronidazole: Alternative Treatment for Ocular and Cutaneous Rosacea in the Pediatric Population. *J Fr Ophtalmol* 2011; 34(10):703-10.
5. Chamailard M, Mortemousque B, Boralevi F, et al. Cutaneous and Ocular Signs of Childhood Rosacea. *Arch Dermatol* 2008; 144(2):167-71.
6. Doan S, Gabison E, Chiambaretta F, et al. Efficacy of Azithromycin 1.5% Eye Drops in Childhood Ocular Rosacea with Phlyctenular Blepharokeratoconjunctivitis. *J Ophthalmic Inflamm Infect* 2013; 3(1):38.
7. Valentín S, Morales A, Sánchez JL, et al. Safety and Efficacy of Doxycycline in the Treatment of Rosacea. *Clin Cosmet Investig Dermatol* 2009; 2:129-40.
8. Doan S, Chiambaretta F, Baudouin C, et al. Evaluation of an Eyelid Warming Device (Blephasteam) for the Management of Ocular Surface Diseases in France: The ESPOIR Study. *J Fr Ophtalmol* 2014; 37(10):763-72.
9. Blephasteam. <http://www.blephasteam.com> Accessed on 15 May 2016.
10. Doan S, Gabison E, Gatinel D, et al. Topical Cyclosporine A in Severe Steroid-Dependent Childhood Phlyctenular Keratoconjunctivitis. *Am J Ophthalmol* 2006; 141(1):62-66.