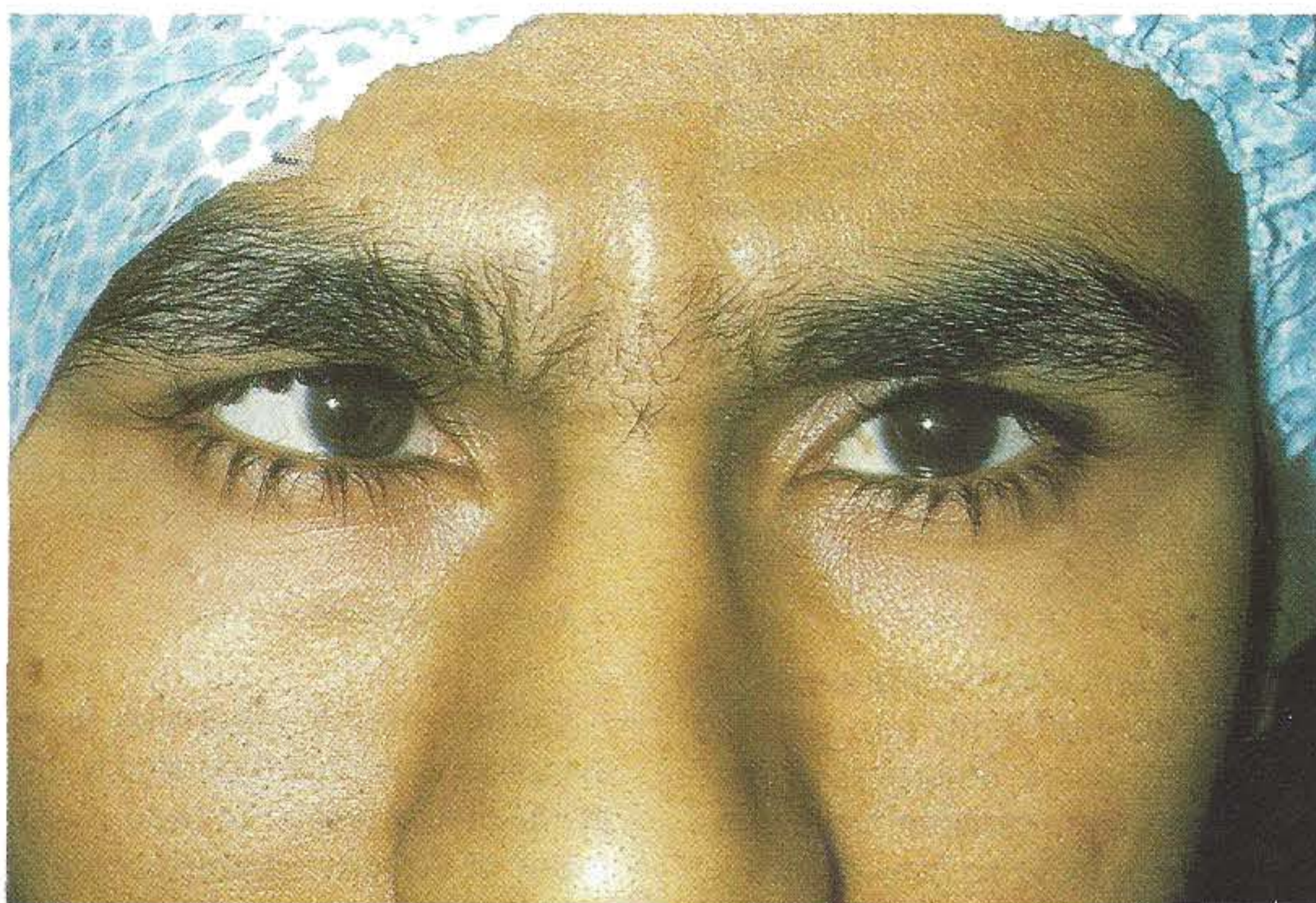


Medical Quiz

Hassan Al Arrayed, FACO,FRCS.ED, Dr Pelin Kaynak

A 25 year old Bahraini male patient showed a squint, deviation of the right eye of 30 prism diopter (15 degrees).



Are the following statements true or false ?

1. Diagnosis of esotropia is correct.
2. Operation will help in correcting his squint.
3. There is high possibility that his right eye vision is poor (Amblyopia).

Answers on page57