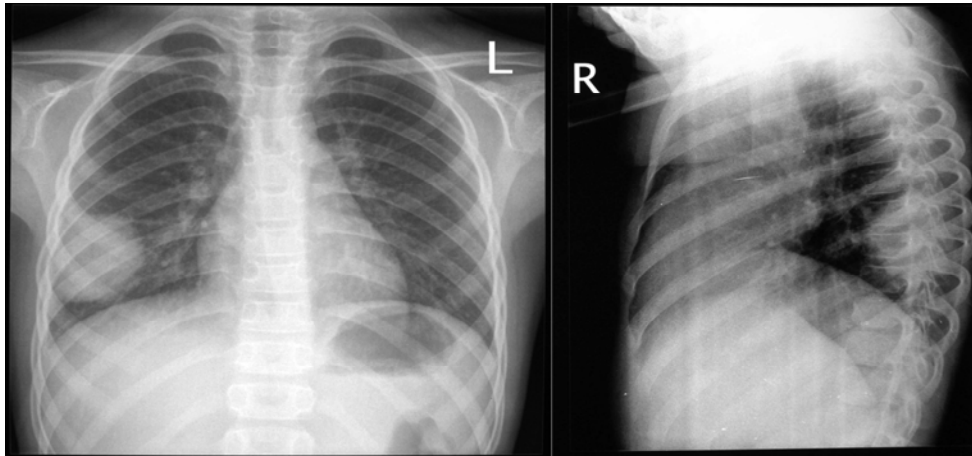


## **MEDICAL QUIZ**

Saeed Alhindi, MD, CABS, FRCSI\* Mahmood Abbas, MD, CABS, EBPS\*

A seven years old girl was admitted to Salmaniya Medical Complex with symptoms of cough and fever of one day duration. There was no other significant past history. On admission, her body temperature was 38°C. The pulse was 120/min, respiratory rate was 35/min. The blood pressure was 80/60 mm Hg. Physical examination showed pharyngeal erythema and chest auscultation was normal. Her chest X-ray is displayed below.



- Q1.** What is the most likely diagnosis?  
**Q2.** Describe the lesion?  
**Q3.** Mention three differential diagnoses?

Answers on page No.....

---

\* Consultant  
Department of Surgery  
Salmaniya Medical Complex  
Kingdom of Bahrain