

Four Year Old Child with Breakthrough Varicella Leading to Pancytopenia

Khalid Kakish, MD, FAAP* Ratna B Basak, MRCP** Jamila Al Dhuhouri, MBBS***
Sanjoy Chakraborty, PhD****

A previously healthy 4-year old child received Varicella Zoster Vaccine 12 weeks prior to presentation. He developed breakthrough varicella which was complicated by pancytopenia which was refractory to all modalities of treatment necessitating Bone Marrow Transplantation.

Bahrain Med Bull 2009; 31(2):

Chickenpox or varicella is a common disease in children¹. While it is often a mild illness in the majority, it can cause substantial morbidity and mortality in immunocompromised children and adults. Due to substantial increase in reports of encephalitis, pneumonia and secondary skin infections, many practitioners are encouraging vaccination against varicella to children above the age of one year².

While the incidence of varicella significantly declines after vaccine administration, varicella can still occur in vaccinated children 42 days after vaccination (www.cdc.gov). It is then called breakthrough varicella. The breakthrough disease is often mild, the rash mostly maculopapular not vesicular, with less constitutional symptoms.

The aim of this paper is to report a child who developed breakthrough varicella 12 weeks after varicella vaccination that was complicated by pancytopenia resistant to all modalities of treatment.

THE CASE

A previously healthy 4-year old boy, who had received Varicella Zoster Vaccine 3 months earlier, presented with a 2-day history of fever and maculopapular vesicular rash. He apparently looked well, was afebrile with normal vital signs. The boy had ecchymotic patches on the elbows and multiple purpuric skin lesions around the eyes with bilateral subconjunctival hemorrhages. There was no organomegaly and his neurological examination was normal. However, his 3-year old sibling who received vaccination at the same time had recovered from chicken pox 10 days ago without any further complications.

* Consultant Pediatrician

** Specialist Pediatrician

*** Resident in Internal medicine

Department of Pediatrics

Al Ain Hospital

United Arab Emirates

**** Lecturer

New York City College of Technology

CUNY, Brooklyn

New York 11201

Initial investigation showed pancytopenia with WBC $2.4 \times 10^9/L$, absolute neutrophil count (ANC) 0.313 (12.8%), absolute lymphocyte count (ALC) 1.72 (70.5%), platelet count $9.3 \times 10^9/L$, normal hemoglobin, reticulocytes 0.8%, serum CRP 6mg/L, ESR 26 mm. Coagulation studies were normal, direct Coombs test was weakly positive, and EBV, Hepatitis B and C serology were negative.

Intravenous acyclovir with ceftriaxone and clindamycin therapy was initiated and 5 units of platelets were transfused. The blood culture and the swab cultures were sterile. With no improvement in the blood count over the next 72 hours, 2 doses of intravenous immunoglobulins (IVIG) were administered on the 3rd and 6th day. Bone marrow aspiration was carried out on the 6th day and showed a hypocellular marrow with no evidence of malignancy. Bone marrow biopsy showed 10-15% cellularity and 20% regenerating cells (Figure 1). CD56 and CD59 markers were positive.

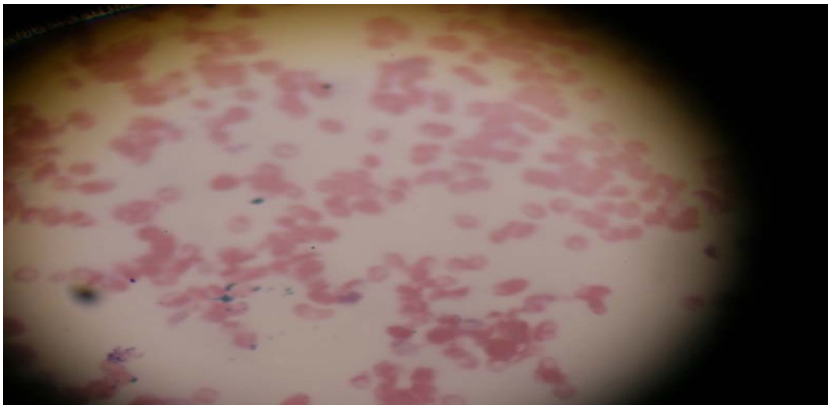


Figure 1: Bone Marrow Aspirate Showing Scarcity of All Cell Lines Indicative of Bone Marrow Hypoplasia

The platelets count continued to decrease and platelet transfusions were administered, followed by pulse dose of methylprednisolone for 3 days. Subsequently, tapering doses of oral prednisolone were given for a week. However, serial blood counts showed only a marginal improvement in white cells and platelet counts. Granulocyte Colony Stimulating Factor (G-CSF) at a daily dose of 100 microgram was administered subcutaneously for 4 days without any satisfactory rise in the count. Bone marrow transplantation was recommended by the hematologist, histocompatible sibling donor found, but the high cost of bone marrow transplant is the main constraint and it is planned to be done in Germany.

DISCUSSION

We hereby describe an otherwise healthy child with breakthrough varicella illness who presented with pancytopenia refractory to platelet transfusion, IVIG, GM-CSF, and pulsed corticosteroids. Although rare, hematological complications have been observed with varicella, and, as far as we could ascertain, no reported cases of pancytopenia have been reported with breakthrough varicella illness as in this case.

In the immunocompetent host, varicella complications are rare, with a reported incidence of 6.3/100,000 population at risk or 1 in 550 cases of varicella requiring hospitalization for such complications. While the most frequent complications are infectious (44%), hematologic complications have been reported in only 4 to 5%^{1,2}.

In large series of children, hematological complications consisted of thrombocytopenia (4 to 12%) or severe anemia (4%)¹. Interestingly, thrombocytopenia seems to be more frequent in adults than children³. Varicella-associated idiopathic thrombocytopenic purpura (ITP) has been described and is usually associated with anti-platelet IgG auto-antibody and responds to antiviral therapy⁴. The anemia is often haemolytic, associated with either anti-I, anti-Pr cold agglutinin or anti-DC⁵. Rarer haematological complications include purpura fulminans due to a transient protein C deficiency or virus-associated hemophagocytic syndrome⁶.

Pancytopenia has also been reported after fulminant varicella associated with pneumococcal sepsis⁷. The pancytopenia may persist for months during which the child remains at risk of severe infections. The duration of the pancytopenia may be related to the patient's immune response. Acute lymphocytic leukemia has been reported after fulminant varicella associated with severe neutropenia or with pneumococcal sepsis and severe bone marrow suppression⁷. Surprisingly, in patients with a variety of hematological disorders, varicella zoster virus (VZV) infections have been shown to be associated with a more rapid and sustained improvement of bone marrow function with treatment, suggesting that VZV infection causes stimulation of bone marrow activity⁸. It may be postulated that this hyperstimulation may be associated with the risk of developing leukemia after varicella-associated bone marrow aplasia.

The pathophysiology of the haematological complications is not clear. Enhanced clearance of platelets by the reticuloendothelial system is considered to be, at least in part, responsible for the thrombocytopenia which occurs during the viral illness and which may be secondary to molecular mimicry between viral antigens and host proteins. Immunoblot analysis of the anti-platelet antibodies identified several platelet surface glycoproteins, glycoprotein V (GPV), GPIb, GPIIb, GPIIIa which may be the target antigen in autoimmune thrombocytopenia. Virus-specific antibodies occurring in children with varicella-associated acute ITP have been shown to cross-react with normal platelet antigens, suggesting a transient autoimmune mechanism causing the thrombocytopenia⁹.

As most hematological complications are usually self limited, the protracted course with the lack of response to all treatment modalities in the child we reported may suggest a pre-existing immune deficiency. Previously undiagnosed IgG2/IgA deficiency was later identified in children with autoimmune neutropenia and ITP secondary to a varicella infection¹⁰.

The management of hematological complications during varicella is fraught with difficulties. The use of corticosteroids during the acute infection carries the risk of dissemination but is of proven value when bone marrow hypoplasia is diagnosed. The administration of high-dose intravenous methylprednisolone has been reported and has led to the normalization of bone marrow function.

The risk of intracranial bleed associated with thrombocytopenia is high and platelet transfusions may be required. Intravenous immunoglobulins (IVIG) may also be considered in view of the immune mediated hematological abnormalities.

CONCLUSION

We report a child who developed breakthrough varicella 12 weeks after varicella vaccination that was complicated by pancytopenia resistant to all modalities of treatment.

Chickenpox is one of the common viral illnesses of children, the incidence of which have declined significantly with vaccination. Although extremely rare, all children who develop pancytopenia secondary to varicella or breakthrough varicella should undergo all tests to rule out preexisting immunodeficiency before further treatment.

REFERENCES

1. Ziebold C, von KR, Lang R, et al. Severe Complications of Varicella in Previously Healthy Children in Germany: a 1-year Survey. *Pediatrics* 2001; 108(5): E79.
2. Peterson CL, Mascola L, Chao SM, et al. Children Hospitalized for Varicella: A Prevaccine Review. *J Pediatr* 1996; 129(4): 529-36.
3. Bovill B, Bannister B. Review of 26 Years' Hospital Admissions for Chickenpox in North London. *J Infect* 1998; 36(suppl)1: 17-23.
4. Hamada M, Yasumoto S, Furue M. A Case of Varicella-Associated Idiopathic Thrombocytopenic Purpura in Adulthood. *J Dermatol* 2004; 31(6): 477-9.
5. Sanchis CJ, Carbonell UF. Autoimmune Hemolytic Anemia with Anti-DC Specificity Following a Primary Infection by Varicella Virus. *Haematologica* 1997; 82(4): 508-9.
6. Canpolat C, Bakir M. A Case of Purpura Fulminans Secondary to Transient Protein C Deficiency as a Complication of Chickenpox Infection. *Turk J Pediatr* 2002; 44(2): 148-51.
7. Helft DA, Correa H, Rojas P, et al. Acute Lymphocytic Leukemia after Fulminant Varicella Associated with Severe Neutropenia. *South Med J* 2002; 95(9): 1074-5.
8. Al-Anazi KA, Al-Jasser AM, Evans DA. Effect of Varicella Zoster Virus Infection on Bone Marrow Function. *Eur J Haematol* 2005; 75(3): 234-40.
9. Wright JF, Blanchette VS, Wang H, et al. Characterization of Platelet-Reactive Antibodies in Children with Varicella-Associated Acute Immune Thrombocytopenic Purpura (ITP). *Br J Haematol* 1996; 95(1): 145-52.
10. Sugita K, Owada Y, Ozawa T, et al. An Infant with Both Autoimmune Neutropenia and Idiopathic Thrombocytopenia with IgG2/IgA Deficiency. *Int J Hematol* 1993; 57(1): 27-30.