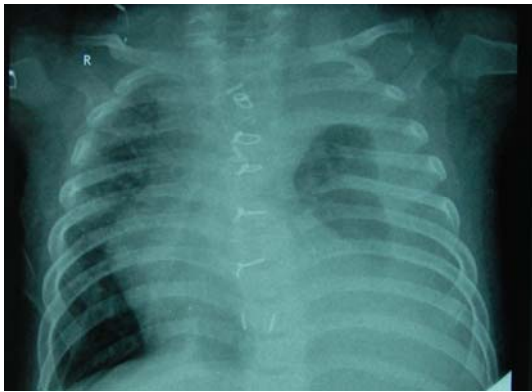


Medical Quiz

Saeed Alhindi, MD, CABS, FRCSI*

A Twelve month old male child presented with history of respiratory distress of three days duration. This patient underwent major cardiac surgery two weeks prior to this presentation. On examination, the patient was in respiratory distress with decreased air entry in the left chest. His Blood pressure and temperature were normal. Chest X-ray was taken (Figure 1). Chest tube inserted and fluid came as milky in colour.



- Q.1.** What is your diagnosis?
- Q.2.** Describe the findings on the chest X-ray.
- Q.3.** What is the next step after inserting the chest tube?