

## The Lost Guide Wire

Ghazi Y Ismael, MBBS\* Dhafer M Kamal, MD, MSc, FRCS (Canada)\*\*

**A guide wire was lost during insertion of a femoral arterial line in a sick patient in the Intensive Care Unit. This was successfully managed by surgical retrieval of the wire. The principles of central vascular catheter insertion and the current interventions to deal with guide wire loss is discussed in this report.**

***Bahrain Med Bull 2010; 32(2):***

Percutaneous central vascular catheter (CVC) insertion is commonly used in intensive care units (ICU) and emergency departments<sup>1</sup>. However, life-threatening complications could be associated with this relatively minor procedure when performed by inexperienced physicians. Some of the most common complications are transient arrhythmias, inadvertent arterial puncture (with hematoma or excessive bleeding), pneumothorax, hemothorax or hemomediastinum, air embolism, line infection and sepsis, and occasionally the loss of a guide wire or catheter fragments<sup>1,2</sup>. Loss of a guide wire or catheter is an avoidable complication; it is associated with mortality rate of 20%<sup>3</sup>. Several reports of lost and forgotten guide wires are found in the literature<sup>2,4-6</sup>. Some of these cases were not recognized immediately after catheter insertion or after the post insertion control X-ray. New symptoms or signs, or an X-ray done for unrelated reason confirmed the presence of this complication<sup>3,7,8</sup>. This is largely due to the fact that medical personnel are not familiar with this specific complication<sup>7</sup>.

Factors such as inexperienced operator, lack of supervision by an experienced physician, exhausted and overworked medical staff, and hesitancy are all associated with this type of human error<sup>2,4,6</sup>. Seldinger technique is the most common method used for CVC insertion<sup>3</sup>. Adhering to its principles is known to decrease the incidence of this complication:

- The physician should check the catheter and guide wire carefully for any breakage before the procedure.
- It is mandatory to keep holding the proximal end of the guide wire during the procedure.
- The physician should never push forward the guide wire when encountering a resistance. Instead, removal and inspection of the guide wire for any damage are recommended.
- It is always advisable at the end of the procedure to check the catheter set for the presence of the guide wire. A guide wire must be there.
- Obtain an X-ray after the procedure to confirm proper catheter position and rule out any unexpected complications<sup>3,4,7,9</sup>.

---

\* Intern

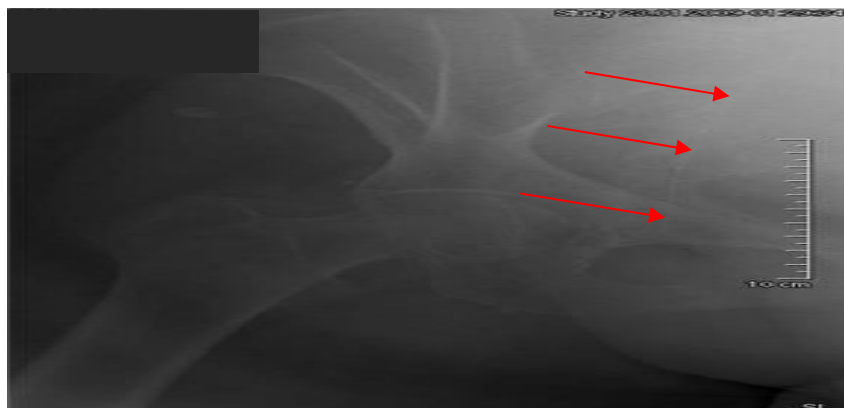
\*\* Consultant Vascular Surgeon  
Department of Surgery  
Division Vascular Surgery  
BDF Royal Medical Services  
Kingdom of Bahrain  
Email: dhaferkamal@hotmail.com

## The Case

A seventy-three year old female, diabetic, hypertensive, dyslipidemic, obese, with functioning renal transplant graft, which was done 17 years ago, she is on immunosuppressants, presented to the hospital complaining of a progressive shortness of breath, productive cough and fever for two weeks. She was admitted to the medical ward and treated for bronchopneumonia.

The patient had a prolonged hospitalization, and in spite of gradual improvement, one month later she suddenly developed significant oxygen desaturation and was admitted to the intensive care unit (ICU) for mechanical ventilation and hemodynamic monitoring. Her blood pressure was continuously measured using an arterial line.


An attempt to insert a new femoral arterial line in the ICU by the resident resulted in lost guide wire. The resident managed to access the vessel but the guide wire “slipped in” and he was not able to retrieve it despite removing the catheter. An X-ray showed the guide wire situated in the right lower pelvis, see Figure 1.



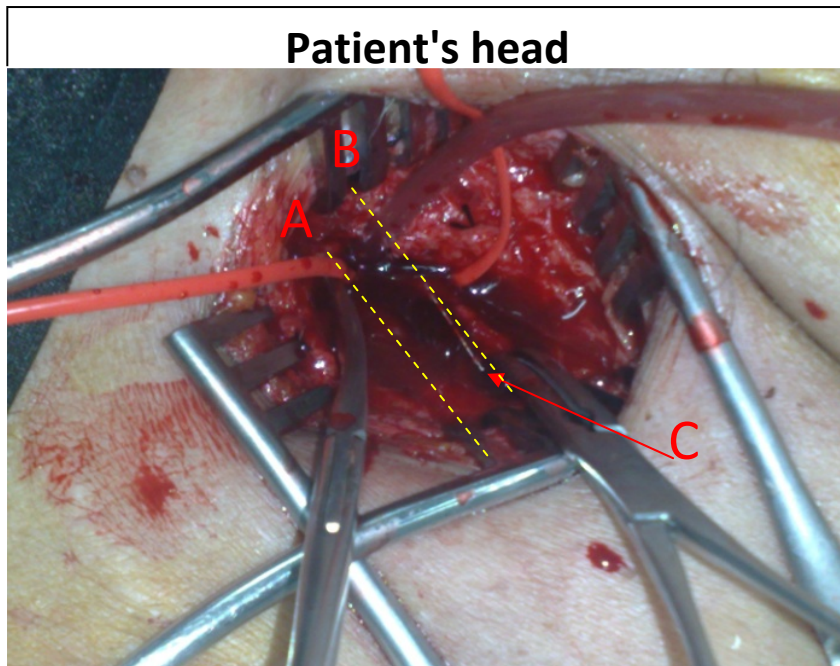
**Figure 1: Arrows Showing the Guide Wire Situated in the Pelvis**

Under local anesthesia, the guide wire tip was not found. Under GA the patient’s groin was explored by converting the local exploration into inguinal longitudinal incision.

The common femoral, the superficial femoral, and the profunda femoris arteries were all dissected out and explored. However, there were no sign of the guide wire or any trauma to the vessels. Intra-operative X-ray via a c-arm image intensifier showed that the guide wire was situated just medial to the common femoral artery as indicated by the tip of the artery forceps placed over the artery (Figure 2). This meant that the wire was most likely to be inside the femoral vein and not the femoral artery. Exploration of the common femoral vein was performed. Minimal amount of venous blood was found in the subcutaneous tissues and overlying the femoral vein. The guide wire was finally seen inside the vein with its distal tip just below the inguinal ligament. The vein and the wire inside it were immediately controlled with a vascular clamp to prevent proximal migration, see Figure 3.



**Figure 2: Showing the Tip of the Artery Forceps Placed at the Common Femoral Artery, the Arrow Is Pointing to the Lower End of the Guide Wire, Note the Medial Relation of the Guide Wire to the Common Femoral Artery**



**Figure 3: (A) Femoral Artery (B) Clamped Femoral Vein (C) Tip of the Guide Wire**

A small transverse venotomy was performed, the 60 cm long guide wire was retrieved and the venotomy was closed with 6.0 (fine) Polypropylene sutures.

Postoperatively, the patient developed a minor lymphatic leak from the incision site. This was successfully treated by conservative measures and the leak stopped completely within one week. She had no other complications related to surgery.

## **DISCUSSION**

Although percutaneous catheterization of central veins or arterial lines is a routine technique, nevertheless, the procedure requires advanced surgical skills, expert supervision, and attention to

details in order to prevent adverse effects<sup>1,2</sup>. Seldinger technique for insertion of intravascular catheters entails puncturing the desired vessel with a needle usually at 45 degree angle from the skin. A guide wire is advanced into the vessel through the needle. Under manual compression, the needle is withdrawn. Incising the skin with a scalpel is sometimes required. A catheter is inserted over the guide wire. The operator should always hold on the distal end of the guide wire while inserting the catheter. The guide wire is then pulled back and the catheter is checked for back flow, carefully flushed with heparinized saline, and secured in place<sup>2,10-13</sup>.

If a guide wire is lost, the first thing to do is to immediately remove the catheter and hope that the wire is still within the catheter and not completely beyond the catheter tip and inside the blood vessel<sup>9,10</sup>.

Currently, there are two methods to manage a lost guide wire; the open method and the percutaneous (endovascular) method. The open method is performed by exploring the blood vessels at the site at which the wire is located as indicated by radiographic imaging. The endovascular method entails retrieval of the wire percutaneously by accessing a vessel remote from the lost wire site. This is done under fluoroscopic guidance. The later method is obviously less invasive than the open method, and more appealing to both physicians and patients. Therefore, it is the method of choice for treating this complication<sup>2,3,6,8</sup>.

The case presented was a sick patient with multiple comorbidities. The guide wire was lost in the early hours of morning when the medical, surgical, and radiographic support is limited to the on-call personnel. Endovascular support was not available at that time. Therefore, a surgical decision was made to retrieve the wire immediately to avoid any intravascular complication. This was successfully achieved with minimal morbidity.

Reports of lost guide wires could be found in the medical literature as early as 1964<sup>7</sup>. Obviously, technological innovations since that time have totally altered the procedures and introduced the endovascular recoveries<sup>9</sup>. The introduction of new retrieval devices that can grasp the endovascular foreign body (wires or catheter pieces) has accelerated the treatment of such cases<sup>9</sup>. However, the use of one specific device is not successful in all cases, and multiple devices might be needed for the successful retrieval of an endovascular foreign body<sup>9</sup>. Snare are not useful if the object has no accessible tip unless it is manipulated first by tip deflecting wires, Dormia baskets or other devices, until it moves into a more favorable position; snares should be the first choice for retrieval of intra vascular foreign bodies<sup>9,12</sup>. If endovascular solutions facilities are not available or unsuccessful, retrieval of the wire by open surgical method should be the next step<sup>14,15</sup>.

Should the guide wire be left in place if the patient is asymptomatic? Obviously, it is unnatural to leave a foreign body anywhere in the human body, let alone in the intravascular tree<sup>6</sup>. In some reported cases, no attempts were made to retrieve the guide wire because it appeared to be stationary and harmless and the patient was asymptomatic. However, years later the patient presented with life threatening complications due to migration of the foreign body to the inferior vena cava or even to the heart causing cardiac tamponade<sup>6,8</sup>.

## CONCLUSION

**Although percutaneous catheterization of central veins and arteries is a common and popular technique, nevertheless, the procedure requires advanced surgical skills, expert supervision, and attention to details in order to prevent adverse effects. The operator must adhere to the principles of the Seldinger technique, and hold onto the guide wire at all times until removal from the vessel. If and when available, endovascular retrieval of a lost guide wire is favored over open surgery. However, definitive management should not be delayed.**

## REFERENCES

1. Shapiro ML, Angood PB. Patient Safety, Errors, and Complications in Surgery. In: Brunicaardi FC, Andersen DK, Billiar TR, et al, eds. Schwartz's Principles of Surgery. Volume-1, 8<sup>th</sup> ed. New York: McGraw-Hill, 2005; 37.
2. Bream PR, Heffernan DS, Shukrallah B. Retrieval of a Wire Lost during Central Venous Catheter Replacement. *Endovascular Today* 2008; 38-41.
3. Schummer W, Schummer C, Gaser E, et al. Loss of the Guide Wire: Mishap or Blunder? *Br J Anaesth* 2002; 88: 144-6.
4. Heberer M, Moser J, Dürig M, et al. Prospective Study of Complications of Central Venous Catheters. *Infusions Ther Klin Ernähr* 1984; 11: 254-61.
5. Dotter CT, Roesch J, Bilbao MK, et al. Transluminal Extraction of Catheter and Guide Fragments from the Heart and Great Vessels: 29 Collected Cases. *AJR* 1971; 111: 467-72.
6. Thomas J, Sinclair-Smith B, Bloomfield D, et al. Non surgical Retrieval of a Broken Fragment of Steel Spring Guide from Right Atrium and Inferior Vena Cava. *Circulation* 1964; 30: 106-8.
7. Thomas KPE, Rosenblatt M, Pollak JS, et al. Retrieval of Intravascular Foreign Bodies: Experience in 32 Cases. *AJR* 1995; 164: 1259-64.
8. Perez-Diez D, Salgado-Fernandez J, Vázquez-González N, et al. Percutaneous Retrieval of a Lost Guide Wire that Caused Cardiac Tamponade. *Circulation* 2007; 115: 629-31.
9. Taslimi R, Safari S, Kazemeini A, et al. Abdominal Pain due to a Lost Guide Wire: A Case Report. *Cases Journal* 2009; 2: 6680.
10. Arya VK, Kumar A. Technique for Retrieval of J-tip Guide-Wire without Withdrawing Introducer Needle during Central Venous Cannulation by Seldinger Technique. *Anesth Analg* 2004; 98: 553-4.
11. Mitchell N. A Sticky Problem with a Guide Guide-Wire. *Anaesthesia* 1996; 51(8): 799.
12. Cekrige S, Weiss JP, Foster RG, et al. Percutaneous Retrieval of Foreign Bodies: Experience with the Nitinol Goose-Neck Snare. *J Vasc Interv Radiol* 1993; 4: 805-10.
13. Sven-Ivar Seldinger. Catheter Replacement of the Needle in Percutaneous Arteriography (A New Technique). *Acta Radiologica* 1953; 39: 368-76.
14. Rossi P, Pavone P. Angiographic Management of Vascular Obstruction in Interventional Radiology. In: Dondelinger RF, Kurdziel JC, eds. *Interventional Radiology*. 1<sup>st</sup> ed. New York: Thieme Medical Publishers Incorporated, 1990: 720.
15. Uflacker R, Lima S, Melichar AC. Intravascular Foreign Bodies: Percutaneous Retrieval. *Radiology* 1986; 160: 731-5.