

## **Villonodular Synovitis of Left Knee Joint: Role of External Radiotherapy**

Mohammed Abdul Naseer, MD\* Sayed Shubbar Mohammed, MD, FRCPC\*\*  
Sara Mathew George, MD, FRCPath\*\*\* Ramachandran Mohan, MSc, PhD\*\*\*\*\*  
Saroj Kumar Das Majumdar, MD, DNB\*\* Mohammed Abdul Basith, MS\*\*\*\*\*

**We report a case of villonodular synovitis of left knee joint treated with surgery and adjuvant postoperative external radiotherapy. The patient presented with long standing history of left knee joint swelling and pain which restricted his daily activities. He did not get relief with pain killers. The patient was operated for maximal excision of synovial tissue. Histology confirmed the diagnosis of villonodular synovitis. Postoperative left knee joint MRI showed residual disease. He received adjuvant external beam radiotherapy. Currently, he is free of disease and disability after four years.**

*Bahrain Med Bull 2011; 33(2):*

Pigmented Villonodular Synovitis (PVNS) is a rare proliferative disorder of the synovium affecting any joint but frequently found in the knee<sup>1</sup>. Definitive diagnosis is made histologically<sup>1</sup>. PVNS occurs in two forms: focal lesions, usually called tenosynovial giant cell tumor (TGCT), and a diffuse form<sup>2</sup>. Both are morphologically and biologically similar, but diffuse PVNS is clinically aggressive and has the tendency for local recurrence but not metastatic potential<sup>3,4</sup>. The lesions are best visualized using magnetic resonance imaging (MRI), which reveals characteristic low signal intensity because of hemosiderin deposition<sup>5</sup>. The primary treatment is surgical removal but complete resection may be difficult due to the diffuse nature of the disease<sup>6</sup>. External beam radiation is used as adjuvant treatment to prevent local recurrence and improve local control<sup>7,8</sup>.

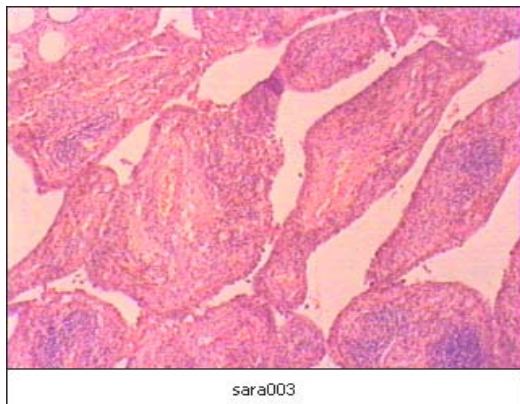
The aim of this presentation is to report a rare case of villonodular synovitis of left knee joint treated with surgery and external beam radiotherapy.

---

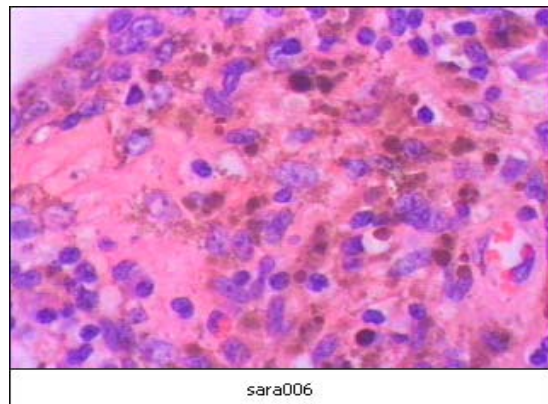
\* Chief Resident  
\*\* Consultant  
Department of Oncology & Hematology  
\*\*\* Consultant  
Department of Pathology  
\*\*\*\* Chief Resident  
Department of Orthopedic  
\*\*\*\*\* Chief Physicist  
Department of Oncology & Hematology  
Salmaniya Medical Complex  
Kingdom of Bahrain  
Email: drnaseermohd@gmail.com

### **THE CASE**

The patient is a forty years old Bahraini gentleman, who had no significant past medical history. He is a heavy vehicle driver and chronic smoker since 25 years. He presented with the history of left knee joint swelling associated with pain of 3 years duration and limitation of left knee joint movements. He denied any history of trauma. He underwent left knee synovectomy in October 2006. At surgery, the growth was extending into the intercondylar notch and underneath the lateral meniscus. The lateral meniscus had to be lifted up after incising the anterior horn. All the synovium removed from the lateral compartment with the one extending to the popliteal hiatus region. After excision of synovium, cauterization was done at places of attachment to bone and in the intercondylar notch area. The meniscus was repaired. The histopathology was reported as villonodular synovitis, see figure 1.



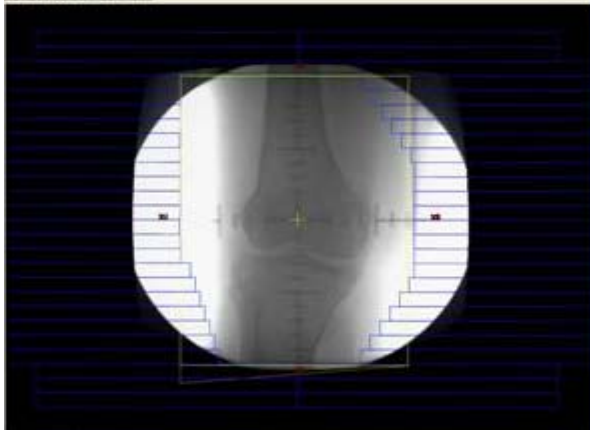
**Figure 1 (A)**



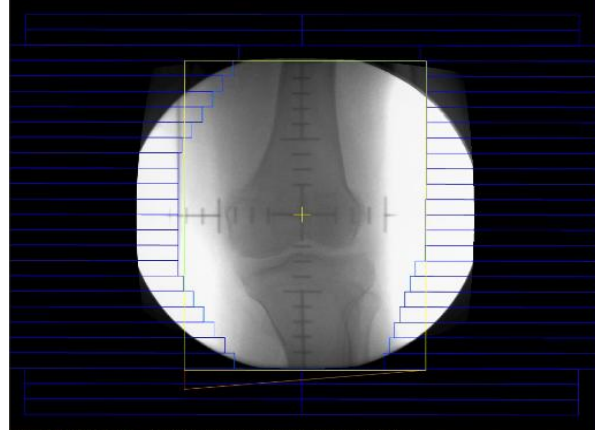
**Figure 1 (B)**

**Figure 1(A): Low Power View Showing the Proliferative Synovial Process with Villonodular Fronds (H&E Stain 100x Magnification), (B): High Power View Showing Mononuclear Stromal Cell Infiltrate in the Synovial Membrane, Hemosiderin-Laden Macrophages Giving the Characteristic Brown Color and Few Lymphocytes (H&E Stain 400x Magnification)**

The postoperative MRI of Left knee, taken December 2006, showed residual disease in the posterior joint compartment within the popliteal recess and around the cruciate ligament. He was referred to Oncology department for postoperative external radiotherapy. He was treated with external beam radiotherapy, three dimensional conformal radiation (3DCRT) techniques by anteroposterior opposed fields to a total dose of 35 Gy in 15 fractions with adequate tolerance, see figure 2. The patient had follow up MRI of left knee joint at regular intervals. The last MRI was taken in November 2010; it did not show any evidence of recurrent disease. However, small amount of joint effusion was seen in the joint space associated with minimal hemosiderin deposition. Clinical examination showed post-radiation skin pigmentation and movement range between 0 - 130°. He had no significant joint pain and no evidence of left leg edema. There was no indication of recurrence four years postoperatively.



**Figure 2(A)**



**Figure 2(B)**

**Figure 2 (A): DRR of Anteroposterior Portal of Radiation Treatment Field, (B): DRR of Posteroanterior Portal of Radiation Treatment Field**

## DISCUSSION

Pigmented villonodular synovitis is a proliferative disorder found in the synovial joints and tendon sheaths; it is most commonly seen in the knee<sup>9</sup>. It is usually monoarticular; polyarticular involvement is rare<sup>10</sup>. The arthroscopic features and histology should alert the surgeon to avoid unnecessary amputation<sup>1,11</sup>.

Pathologically, the lesion is characterized by the proliferation of fibroblasts and histiocytic mesenchymal cells below the synovial lining cells, foam cells and iron deposits are secondary changes<sup>1</sup>. Immunohistochemical profile is not well characterized. CD68 is consistently seen in mononuclear cells and histiocytes<sup>1</sup>. Scattered dendritic cells expressing S-100 were seen in 67% cases<sup>12</sup>.

The treatment of choice is surgical excision, but complete resection may be difficult depending upon the area to be resected (partial versus complete synovectomy) and the joint involved<sup>6</sup>.

Postoperative radiation can improve the local control rate. Local control rate for surgery alone varies from 44-92%<sup>6</sup>.

The optimal dose and fractionation schedule of radiation for PVNS is unclear<sup>3</sup>. Some have reported using doses as low as 16 - 20 Gy without recurrence, whereas others have used doses as high as 50 Gy without complications<sup>7,13,14</sup>. Myers et al recommended a dose of 36 Gy with conventional fractionation. However, a cumulative dose of 40 Gy in 20 fractions seems to be effective in preventing recurrence and is safe from late complication<sup>3,7</sup>.

The patient presented had responded well to 35 Gy in 15 fractions (an equivalent dose of 42 Gy with conventional fractionation). The final pathway of PVNS of knee is total joint destruction leading to joint replacement. Postoperative external beam radiation minimizes this complication in these young healthy patients. As an alternative to external beam radiation treatment, some

have treated residual PVNS with intraarticular injection of radionuclides (radiosynoviorthesis) such as  $^{90}\text{Y}$ trium<sup>15</sup>.

## CONCLUSION

**Pigmented villonodular synovitis is a benign disorder of the knee joint. Surgery is the treatment of choice since local recurrence is very much common after surgery.**

**Postoperative adjuvant external radiotherapy is safe and effective modality to control the disease and local recurrence for long time.**

---

**Author Contribution:** All authors share equal effort contribution towards (1) substantial contributions to conception and design, acquisition, analysis and interpretation of data; (2) drafting the article and revising it critically for important intellectual content; and (3) final approval of the manuscript version to be published. Yes

**Potential Conflicts of Interest:** No

**Competing Interest:** None, **Sponsorship:** Roche Company

**Submission date:** 05/12/2010 **Acceptance date:** 15 April 2011

**Ethical approval:** Approved by Oncology Department

## REFERENCES

1. Radha S, Afroz T, Vidya SJ. Pigmented Villonodular Synovitis. *Indian J Orthop* 2006; 40: 38-40.
2. Melissa H, Phuoc T, Pavan B, et al. External Beam Radiation Therapy Enhances Local Control in Pigmented Villonodular Synovitis. *Int J Radiat Oncol Biol Phys* 2009; 75 (1): 183-7.
3. Myers BW, Masi AT. Pigmented Villonodular Synovitis and Tenosynovitis: A Clinical Epidemiological Study of 166 Cases and Literature Review. *Medicine (Baltimore)* 1980; 59: 223-38.
4. Cupp JS, Miller MA, Montgomery KD. Translocation and Expression of CSF1 in Pigmented Villonodular Synovitis, Tenosynovial Giant Cell Tumor, Rheumatoid Arthritis and Other Reactive Synovitis. *Am J Surg Pathol* 2007; 31: 970-6.
5. Goldman AB, DiCarlo EF. Pigmented Villonodular Synovitis. Diagnosis and Differential Diagnosis. *Radio Clin North Am* 1988; 26: 1327-47.
6. Mohler DG, Kessler BD. Open Synovectomy with Cryosurgical Adjuvant for Treatment of Diffuse Pigmented Villonodular Synovitis of the Knee. *Bull Hosp Jt Dis* 2000; 59: 99-105.
7. Berger B, Ganswindt U, Bamberg M. External Beam Radiotherapy as Postoperative Treatment of Diffuse Pigmented Villonodular Synovitis. *Int J Radiat Oncol Bio Phys* 2007; 67: 1130-4.

8. Blanco CE, Leon HO, Guthrie TB. Combined Partial Arthroscopic Synovectomy and Radiation Therapy for Diffuse Pigmented Villonodular Synovitis of the Knee. *Arthroscopy* 2001; 17: 527-31.
9. Docken WP. Pigmented Villonodular Synovitis: A Review with Illustrative Case Reports. *Sem Arthrit Rheumat* 1979; 9: 1-22.
10. Flandry F, Hughston JC, McCann SB, et al. Diagnostic Features of Diffuse Pigmented Villonodular Synovitis of Knee. *Clin Orthop* 1994; 298: 212-20.
11. Jergesen HE, Mankin HJ, Schiller AL. Diffuse Pigmented Villonodular Synovitis of Knee Mimicking Primary Bone Neoplasm. *J Bone Joint Surg (Am)* 1978; 60: 825-9.
12. Perka C, Labs K, Zippel H, et al. Localized Pigmented Villonodular Synovitis of the Knee Joint. *Rheumatol* 2000; 39: 172-8.
13. Ustinova VF, Podliasshuk EL, Rodinova SS. Combined Treatment of the Diffuse Form of Pigmented Villonodular Synovitis. *Med Radio (Mosk)* 1986; 31: 27-31.
14. O'Sullivan B, Cummings B, Catton C. Outcome Following Radiation Treatment for High Risk Pigmented Villonodular Synovitis. *Int J Radiat Oncol Biol Phys* 1995; 32: 777-86.
15. Wiss DA. Recurrent Villonodular Synovitis of the Knee: Successful Treatment with Yttrium-90. *Clin Orthop Relat Res* 1982; 169: 139-44.