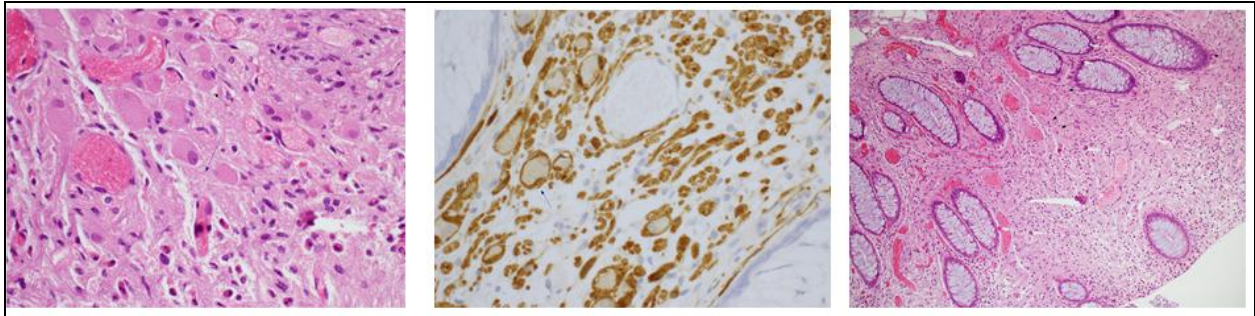


Medical Quiz

Mohamed A Al-Hamar, MD* Suhail Baithun, MD, FRC Path**
Khalid A Al-Sindi, MD, FRC Path***

A thirty-seven years old Indian male presented with left upper quadrant pain and irregular bowel movement. The patient had colonoscopy. Biopsies from stomach, terminal ilium and cecum were taken. A polypoid lesion was noted during colonoscopy in the descending colon from which 10 mm biopsy was taken.



See the microscopic view of the polypoid lesion and answer the following questions.

- Q1.** Describe the abnormality seen in the figures? What is your differential diagnosis?
- Q2.** Name the three types of this tumor which could occur in the intestinal tract.
- Q3.** Name the conditions that can be associated with this tumor.
- Q4.** What are the clinical implications of such tumor?

Answers on page No.109

* Senior House Officer- Histopathology
** Consultant Pathologist
*** Head
Department of Pathology
King Hamad University Hospital
Kingdom of Bahrain
Email: khalid.alsindi@khuh.org.bh