

Pilomatrixoma

Abdulrahman Alsulaiti, MD, BSc* Noof Alshaibani, CABS**
Suhail Baithun, MBCHB, FRCPath*** Mina Girgis, MBBCh, MRCS****

Pilomatrixoma is a benign skin tumor that arises from the hair cell matrix. It is a rare tumor that commonly presents in certain locations of the body. We present a seventeen-year-old female with pilomatrixoma located in the lateral aspect of the right thigh. The tumor is rare and presented in a rare location.

Bahrain Med Bull 2016; 38 (2): 108 - 109

Pilomatrixoma (calcified epithelioma of Malherbe) is an uncommon benign skin tumor that arises from the hair cell matrix. The first description of pilomatrixoma was in 1880; the understanding of this tumor has been on the rise regarding its morphology and clinical presentation. However, there are some difficulties in making a proper diagnosis clinically before the histopathology result. This tumor could present in the head, neck, upper extremities and rarely in lower extremities¹. They are characterized by calcification within the lesion, which makes it feel hard and bony and often results in an angulated shape.

The cause of pilomatrixoma is unknown. It is found to be associated with some genetic causes that affect hair cells which result in cell proliferation and eventually leads to cancer².

The aim of this report is to increase the awareness of pilomatrixoma clinically.

THE CASE

A seventeen-year-old female presented with a mass on the right thigh of about five years duration. The mass was located in the lateral aspect of the right thigh. The mass gradually increased in size; it was painless and no history of trauma or other associated symptoms such as rash, weight loss and fever. The patient denied having any other masses or similar complaint. There was no family history of pilomatrixoma.

The mass was about 2 x 3 cm in size, non-tender, firm, fixed and attached to the skin, but not to the underlying tissue. The mass was excised under local anesthesia; grossly it appeared as a stony hard, irregularly shaped mass with a bluish white discoloration. The biopsy was sent to the histopathology, which revealed the presence of well-circumscribed tumor located in the dermis surrounded by connective tissue capsule, see figure 1. The tissue consists of irregular islands of cells made up of basophilic cells with scanty cytoplasm, indistinct cell borders and dark round nuclei with no mitotic activity. Some of the

cells show the so-called ghost cells, which are pale eosinophilic cells with retained nuclear outlines, see figure 2. The stroma surrounding the epithelium shows fibroblastic proliferation with few inflammatory cells associated with the presence of foreign body giant cells; calcification area has been found.

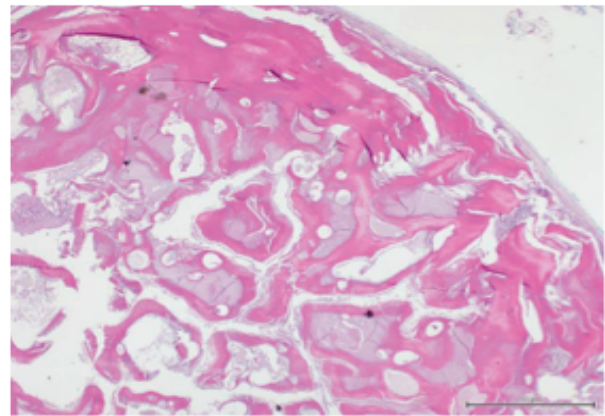


Figure 1: Well-Circumscribed Lesion in the Dermis Surrounded By Connective Tissue Capsule

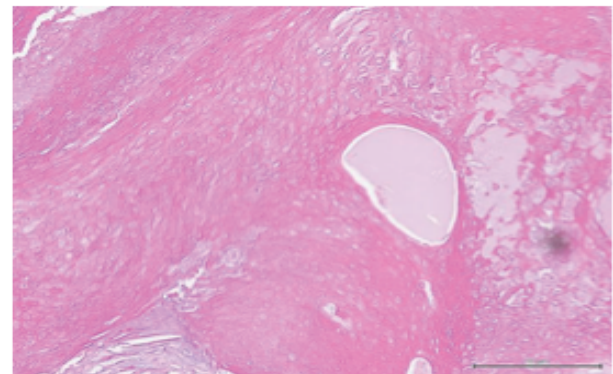


Figure 2: This Highlights the So-Called Ghost Cell

* Intern
** Senior Registrar
Department of General Surgery
*** Consultant
Department of Pathology
**** Senior House Officer
Department of General Surgery
King Hamad University Hospital
Kingdom of Bahrain
Email: Abdulrahman.ALSulaiti@khuh.org.bh

DISCUSSION

Pilomatrixoma is a benign cutaneous neoplasm. In 1880, it was described by Malherbe and Cazenave who thought that the tumor developed from a sebaceous gland³. The histopathology of pilomatrixoma was described in 1922 by Duberluth and Cazenave⁴. A study of pilomatrixomas in 1,568 cases proved that females were more liable than males to develop pilomatrixomas 3:2⁵. However, another retrospective study of 27 cases showed that the female to male ratio was 2:1⁶. Mostly, the tumor presents in children and young adults up to 20 years of age and in the sixth and seventh decade of life⁷.

The tumors' sizes are variable ranging from 4 mm to 35 mm in diameter⁸. Although a study of 10 cases of pilomatrixoma showed that the cause is due to positive BCL 2 which is a proto-oncogene that suppresses the apoptosis function⁹. However, another study mentioned a mutation in CTNNB1 gene that is responsible for regulating and transmitting the inhibition signal that causes the cell to stop dividing¹⁰. A review study of 137 cases of pilomatrixoma revealed that the lesion was found in head and neck, 70%, upper extremity, 22% and hair bearing back, chest and lower extremity, 8%¹¹. Another study of 205 cases of pilomatrixoma revealed that 50% in head and neck, 23.9% in upper limbs and 12.7% in lower limbs. No case was reported in palms, soles and genitalia^{9,11}. Seventy-five percent of cases present with a single lesion less than 15 mm in diameter¹². The rate of correct diagnosis preoperatively is 0-30%¹³. The tumor is often misdiagnosed with other tumors such as cystic lesion, epidermal cyst, dermoid cyst, tuberculoma and granulation tissue^{6,14}.

In this patient, the diagnosis was known after the histopathology result. The tent sign (stretching of skin over the tumor) is pathognomonic of pilomatrixoma¹⁵. The diseases that are associated with pilomatrixoma are myotonic dystrophy, Gardner syndrome, Rubinstein Taybi syndrome, Turner syndrome and sarcoidosis¹⁶⁻¹⁹.

Ultrasound could be used as a non-invasive modality. In a study of 28 pilomatrixoma, the ultrasound showed a hypoechoic and echogenic area. Fine needle aspiration had found to give an accurate diagnosis when two cells are present, shadow cell and basaloid cell. The tumor has a high cellularity, increased ratio of nucleus to cytoplasm and the presence of nucleated squamous cells; it could be misdiagnosed as a squamous cell carcinoma. Surgical excision is the management of pilomatrixoma⁶. The recurrence of the tumor is rare after surgical excision and if it happens it should be suspected of malignant transformation²⁰.

CONCLUSION

Physicians and surgeons still face a difficulty in the diagnosis of pilomatrixoma before the histopathology examination, but it should be suspected clinically.

Author Contribution: All authors share equal effort contribution towards (1) substantial contribution to conception and design, acquisition, analysis and interpretation of data; (2) drafting the article and revising it critically for important intellectual content; and (3) final approval of manuscript version to be published. Yes.

Potential Conflicts of Interest: None.

Competing Interest: None. **Sponsorship:** None.

Submission Date: 17 September 2015.

Acceptance Date: 2 April 2016.

Ethical Approval: Approved by the Research and Ethics Committee, King Hamad University Hospital, Bahrain.

REFERENCES

- Gupta RK, Phang T, Lallu S, et al. Fine-Needle Aspiration Cytology of Pilomatrixoma of the Arm and the Role of Cell Block Examination in the Diagnosis. *Diagnostic Cytopathology* 2005; 32(1):61-62.
- Hassanein AM, Glanz SM, Kessler HP, et al. Beta-Catenin is Expressed Aberrantly in Tumors Expressing Shadow Cells. *Pilomatricoma, Craniopharyngioma, and Calcifying Odontogenic Cyst. Am J Clin Pathol* 2003; 120(5):732-6.
- Malherbe A, Chenantais J. Note Sur 1' Pitheliome Calcifi Des Glandes Sebacees. *Prog Med* 1880; 8:826-37.
- Dubreuilh W, Cazenave E. De l' Epithelioma Calcifie: Etude Histologique. *Ann Dermatol Syphilol.* 1922; 3:257-68.
- Moehlenbeck FW. MD. Pilomatricoma (Calcifying Epithelioma). A Statistical Study. *Arch Dermatol* 1973; 108(4):532-4.
- Zaman S, Majeed S, Rehman F. Pilomatricoma – Study on 27 Cases and Review of Literature. *Biomedica* 2009; 25:69-72.
- Kranjčec I, Roganović J, Jonjić N. Pilomatricoma: A Benign Appendageal Tumor Not Uncommon in Children. *Acta Dermatovenerol Croat* 2015;23(4):308-9.
- Julian CG, Bowers PW. A Clinical Review of 209 Pilomatricomas. *J Am Acad Dermatol* 1998; 39(2 Pt 1):191-5.
- Farrier S, Morgan M. Bcl-2 Expression in Pilomatricoma. *Am J Dermatopathol* 1997 19(3):254-7.
- Lazar AJ, Calonje E, Grayson W, et al. Pilomatricomas Contain Mutations in CTNNB1, the Gene Encoding Beta-Catenin. *J Cutan Pathol* 2005; 32(2):148-57.
- Kwon D, Grekov K, Krishnan M, et al. Characteristics of Pilomatricoma in Children: A Review of 137 Patients. *Int J Pediatr Otorhinolaryngol* 2014; 78(8):1337-41.
- Yencha MW. Head and Neck Pilomatricoma in the Pediatric Age Group: A Retrospective Study and Literature Review. *Int J Pediatr Otorhinolaryngol* 2001; 57(2):123-8.
- Graham JL, Merwin CF. The Tent Sign of Pilomatricoma. *Cutis.* 1978; 22(5):577-80.
- Masuno M, Imaizumi K, Ishii T, et al. Pilomatricomas in Rubinstein-Taybi Syndrome. *Am J Med Genet* 1998; 77(1):81-2.
- Pujol RM, Casanova JM, Egido R, et al. Multiple Familial Pilomatricomas: A Cutaneous Marker for Gardner Syndrome? *Pediatr Dermatol* 1995; 12(4):331-5.
- Handler MZ, Derrick KM, Lutz RE, et al. Prevalence of Pilomatricoma in Turner Syndrome: Findings from a Multicenter Study. *JAMA Dermatol* 2013; 149(5):559-64.
- Cigliano B, Baltogiannis N, De Marco M, et al. Pilomatricoma in Childhood: A Retrospective Study from Three European Paediatric Centres. *Eur J Pediatr* 2005; 164(11):673-7.
- Goufman DB, Murrell GL, Watkins DV. Pathology Forum. Quiz Case 2. Pilomatricoma (Calcifying Epithelioma of Malherbe) *Arch Otolaryngol Head Neck Surg* 2001; 127:218-20.
- Darwish AH, Al-Jalahema EK, Dhiman AK, et al. Clinicopathological Study of Pilomatricoma. *Saudi Med J* 2001; 22(3):268-71.
- Hernández-Núñez A, Nájera Botello L2, Romero Maté A, et al. Retrospective Study of Pilomatricoma: 261 Tumors in 239 Patients. *Actas Dermosifiliogr* 2014;105(7):699-705.