

Medical Quiz

Layla M Thamer, MD, Hakima Al-Hashimi, FRCR,FFR, RCSI

Twelve years old male presented to the accident and emergency department following head injury in a road traffic accident. On examination, the patient was semiconscious, with stable vital signs. Primary Airway, Breathing, and Circulation management was done, including the placement of an endotracheal tube. A post intubation chest radiograph was taken, as shown in figure1. The patient was sent for brain CT, during which he started to develop progressive shortness of breath. His arterial blood gases showed severe hypoxia. Another chest radiograph was taken, as shown in figure 2.

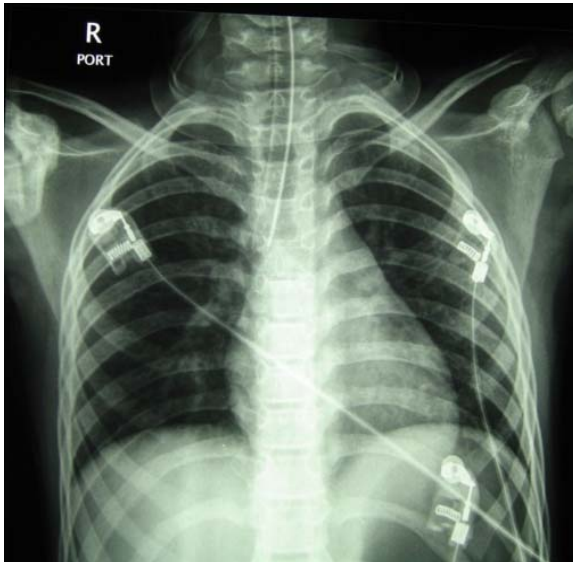


Figure 1

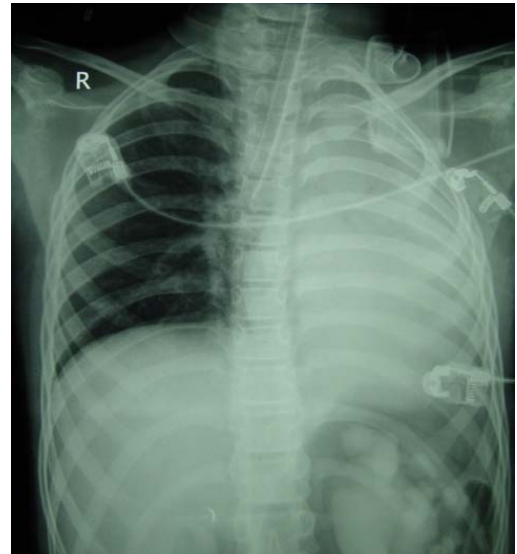


Figure 2

- Q 1. What is the most likely cause of the patient's respiratory distress?
- Q 2. How can this complication be avoided?
- Q 3. What are the other causes for this condition, other than the one encountered in this patient?