

Medical Quiz

Suhair Al-Saad, FRCSI* Hamdi Al-Shinawi, FRCSI**

Eighty-eight years old patient presented to emergency department with intermittent attacks of central abdominal pain and vomiting of undigested food for the last six months. These symptoms became worse in the last one week and were associated with abdominal distension and constipation. There is history of loss of weight but no loss of appetite. There was past history of gastric surgery more than twenty years ago (probably truncal vagotomy and pyloroplasty).

On examination, the patient was generally malnourished, dehydrated and pale. The abdomen was distended with positive succussion splash in the upper abdomen. Bowel sounds were hyperactive. There was a significant lower limb edema.

Blood investigation showed hemoconcentration, elevated urea and creatinine, hyponatremia, hypokalemia, and metabolic alkalosis. In addition, the patient had hypoproteinemia, hypoalbuminemia indicating malnutrition and Iron deficiency anemia.

- Q1.** What are the management immediate measures?
Q2. What is the diagnostic tool shown in the photos and what are the findings?
Q3. What is the most probable diagnosis?
Q4. What are the management options?

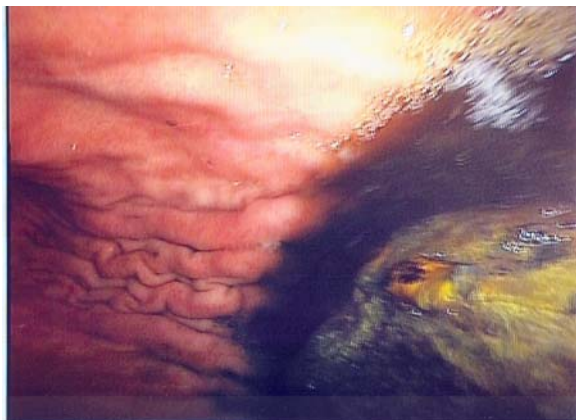


Figure 1



Figure 2

Answers on page No.....

* Consultant Surgeon & Assistant Professor

**Consultant Surgeon & Assistant Professor

College of Medicine

Arabian Gulf University

Kingdom of Bahrain