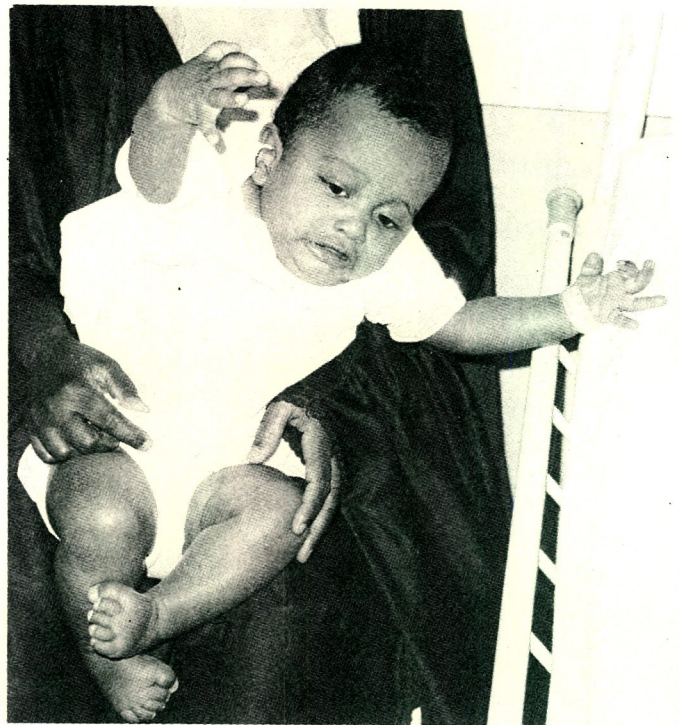
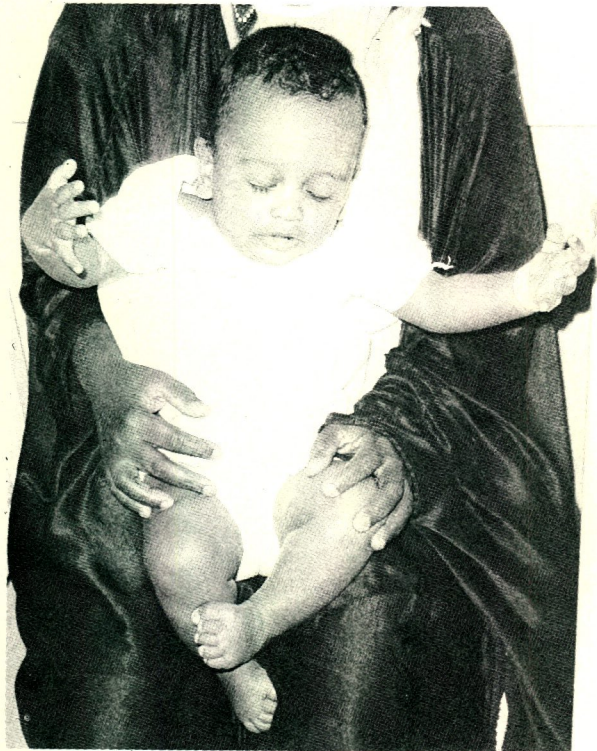
MEDICAL QUIZ

Prepared by
Akbar Mohsin Mohammad★ and
Najeeb S. Jamsheer★★

CASE 1

This is an 8 month old boy admitted to the hospital for investigation. On observation you see what is demonstrated in these two pictures.



★ Chairman,
Paediatric Department,
Salmaniya Medical Centre

★★ Chairman,
Radiology Department,
Salmaniya Medical Centre

Question 1. What is the infant demonstrating ?

Question 2. What specific investigation should be done ?

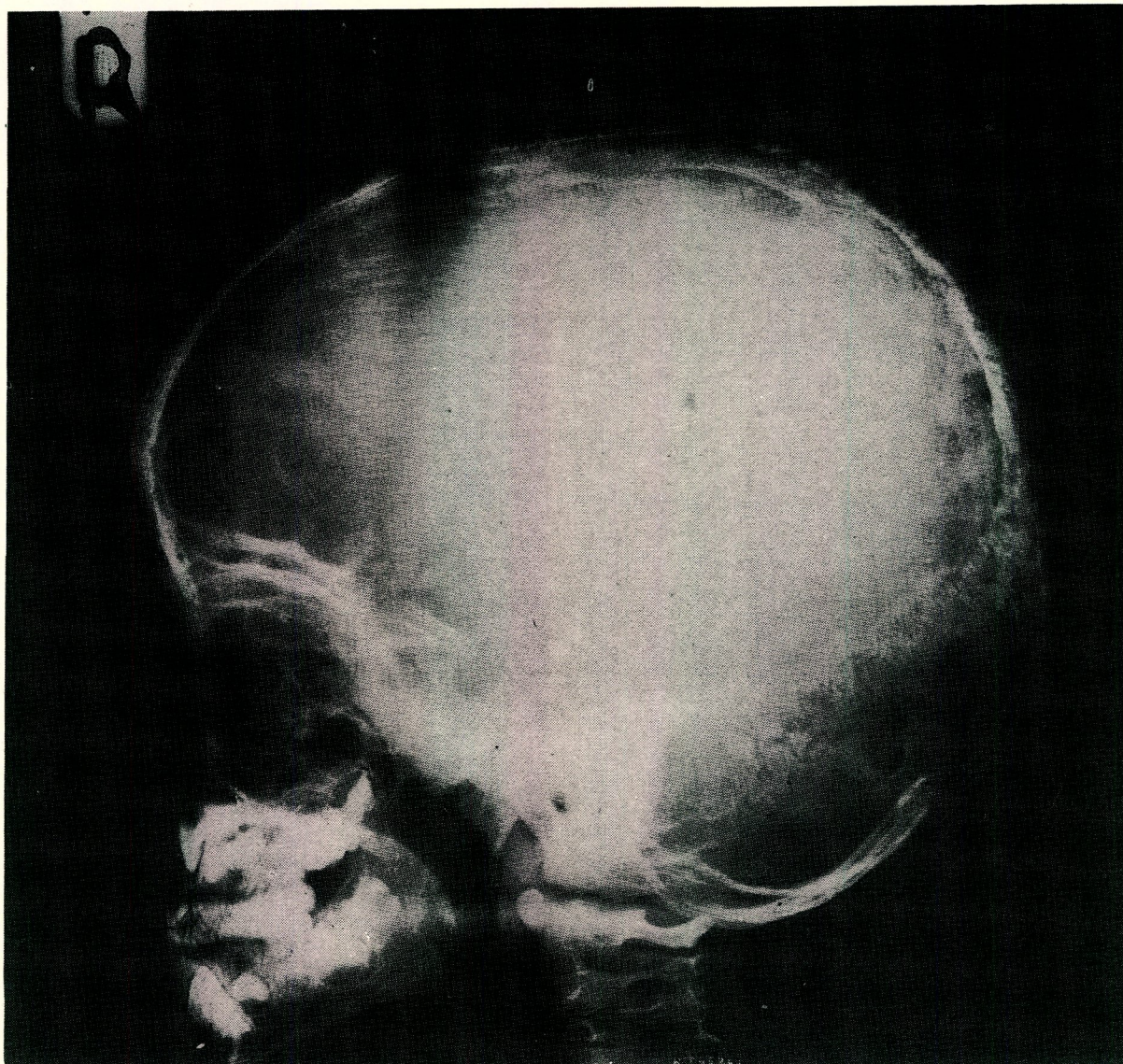
Question 3. What are the findings of this investigation ?

Question 4. What is your diagnosis ?

Question 5. What drug(s) should be tried in treating this patient ?

CASE 2

A lateral skull X-ray of a 4 year old boy



Question 1.

Describe the finding(s).

Question 2.

Enumerate common possible aetiologies.

Question 3.

Choose the most likely possibility.

(Answers on page 46)