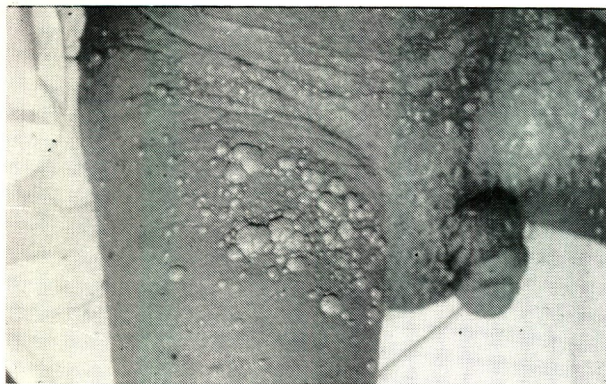

MEDICAL QUIZ

By Ahmed Al-Arrayed*

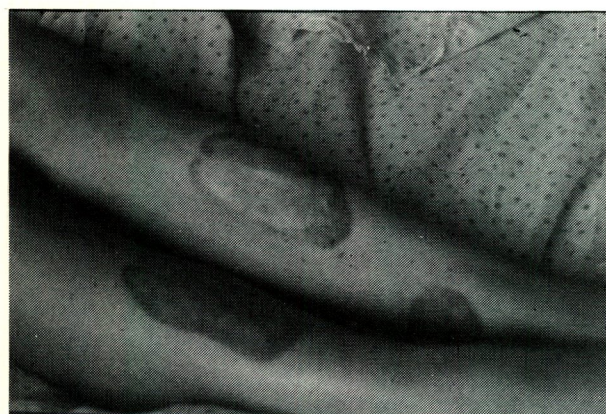
CASE 1



Question 1. What is the lesion?

Question 2. Which condition is associated with this lesion?

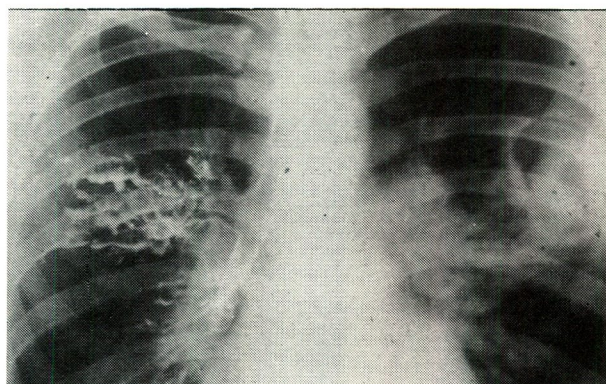
CASE 3



Question 1. What lesion does this slide demonstrate?

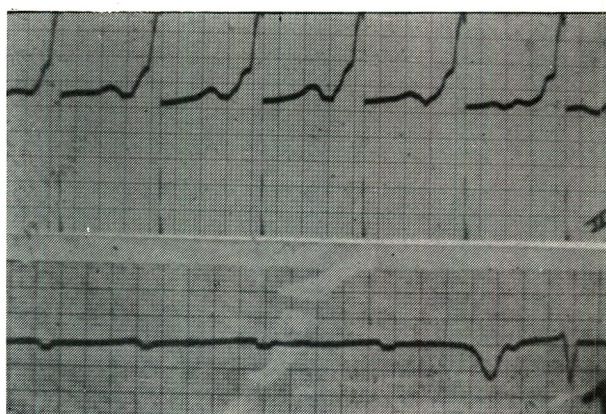
Question 2. What blood test can confirm the diagnosis?

CASE 2



Question 1. A sixteen-year-old boy noted deterioration of his asthma two years before this radiograph. What two abnormalities does it show?

CASE 4



Question 1. What is the diagnosis in the upper ECG?

Question 2. What are the changes in the lower tracing?

Answers on page 38

*Consultant Physician and Incharge of AKU
Department of Medicine, Salmaniya Medical Centre
State of Bahrain