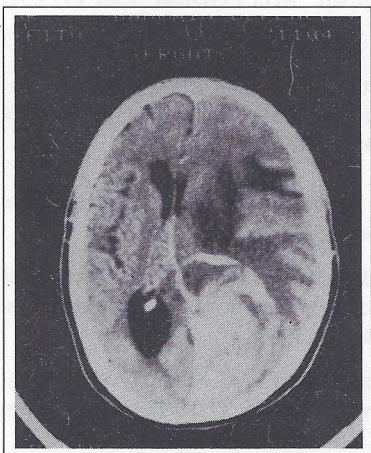


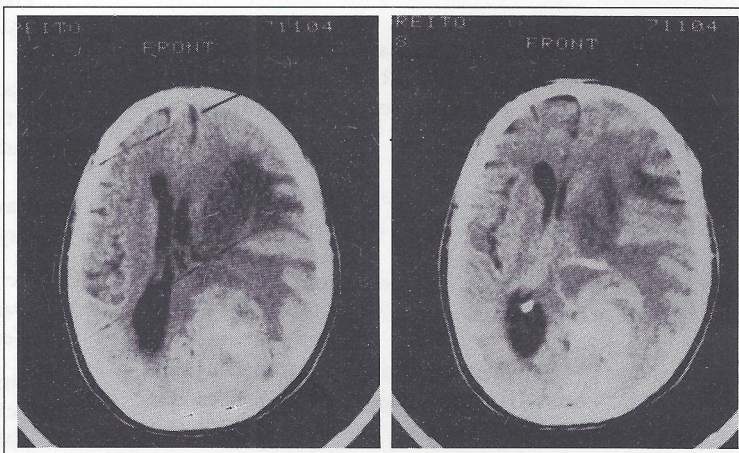# MEDICAL QUIZ

## A Radiologic Case

Dr Ademakinwa M Adekunle



**Pre-Contrast**



**Post-Contrast**

A 58-year-old woman brought to the hospital in a coma following seizures.

- Questions:
1. What are the findings on these CT scans?
  2. What is your impression?
  3. What is the differential diagnosis?

Answers on page 37