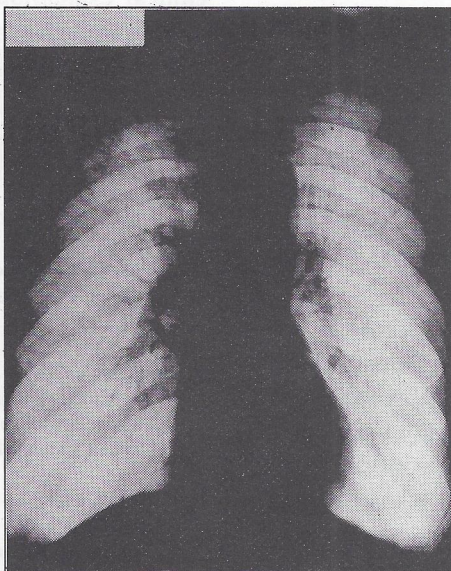


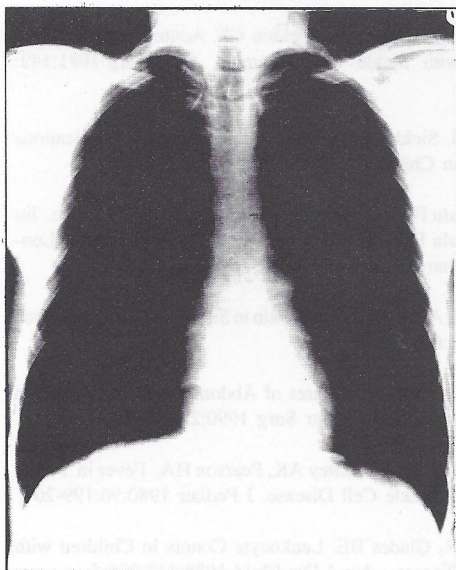
# MEDICAL QUIZ

Najeeb Jamsheer

- Q1. Provided is a frontal chest radiograph of a 60 year old gentleman with history of chronic cough and increasing dyspnea over the last few years. He gives history of smoking 30 cigarettes per day for as long as he can remember. List the major findings ?



- Q2. The frontal (Fig 2a) and lateral (Fig 2b) chest radiographs are of a 35 year old gentleman referred for pre-employment chest x-ray. He has no respiratory symptoms and no history of smoking. Also no family history of respiratory illnesses.



1. Is this chest radiograph normal ?
2. If abnormal, list the abnormality(ies) ?



Answers on page 37