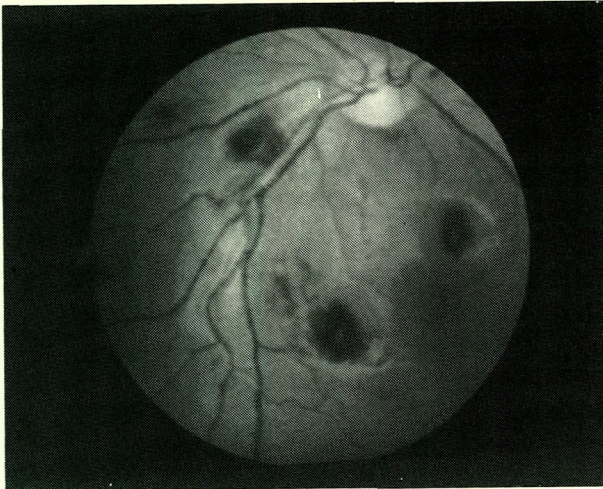


MEDICAL QUIZ

By Hassan H Al Arrayed*

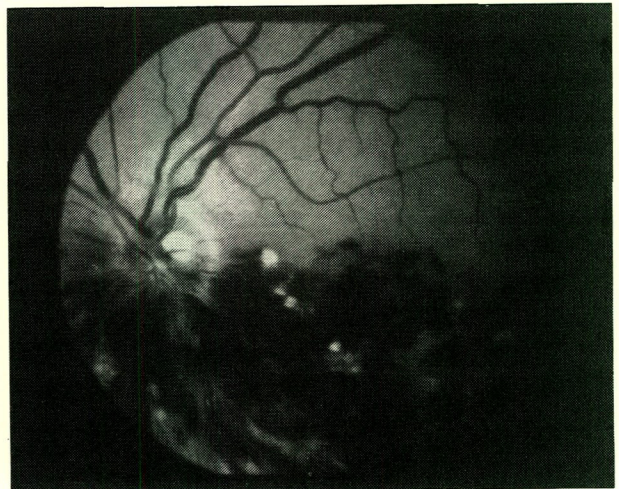
CASE 1



Male Bahraini Middle Age

- Q1.** What are these lesions called?
- Q2.** In what condition could this be seen?
- Q3.** Does optic nerve looks normal?

CASE 2



Fundus of old male patients.

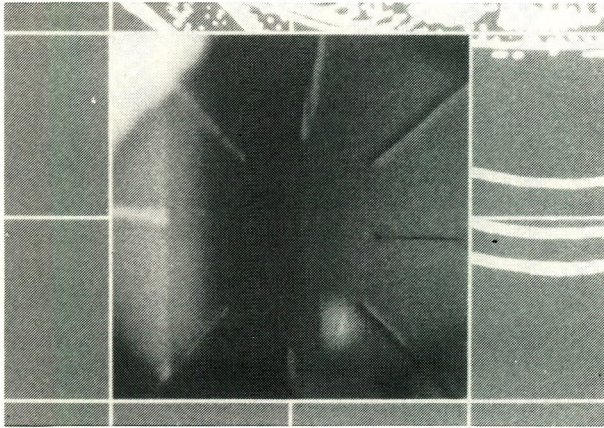
- Q1.** What is the lesion?
- Q2.** Why is it taking only half the fundus?
- Q3.** Could the patient be hypertensive?

* Consultant Ophthalmologist
Salmaniya Medical Centre
State of Bahrain

Medical quiz should be submitted to :

Dr. A. Mohsin or
Dr. N. Jamsheer

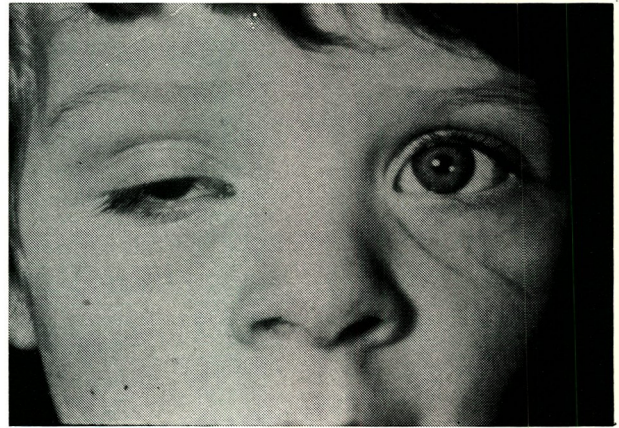CASE 3



This is a photograph of a cornea.

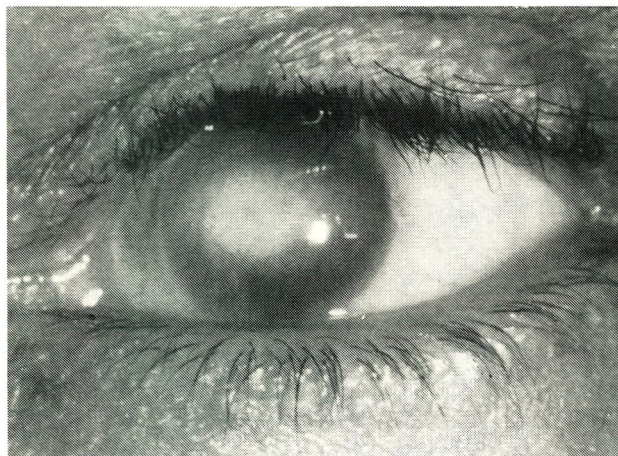
- Q1.** What are these lines?
- Q2.** For what cases are these procedures done?
- Q3.** Where is it mostly done?

CASE 4



- Q1.** Which eye is abnormal?
- Q2.** What correction should be done?
- Q3.** Is 3rd nerve problem the only cause?

CASE 5



Male Bahraini patient age 35 years.

- Q1.** What is the lesion?
- Q2.** What could be the most common cause of such lesion in Bahrain?
- Q3.** What treatment would you advise?