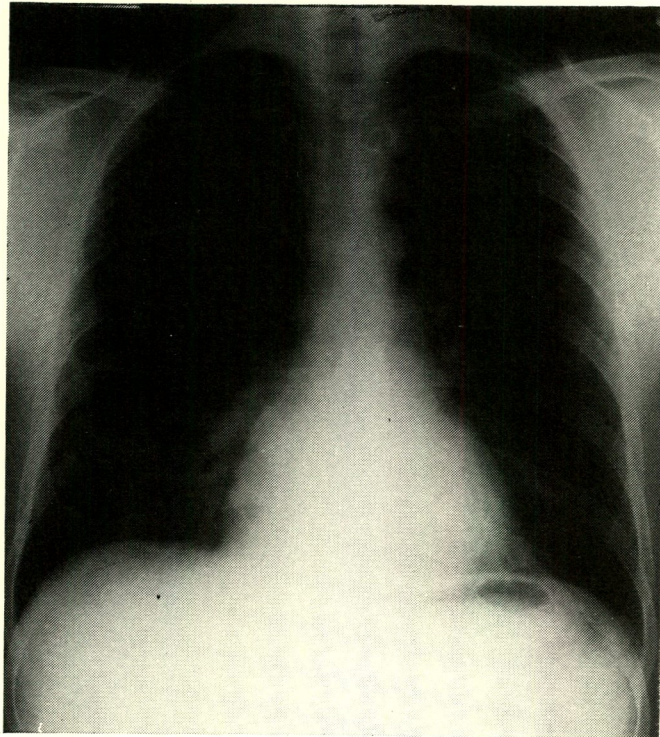


# MEDICAL QUIZ

This is a frontal chest film of a 36 year old gentleman who presented to the outpatient clinic with a few days history of increasing shortness of breath. He smokes 20 cigarettes per day.



## QUESTIONS

1. What is (are) the radiological abnormality(ies)/diagnosis?
2. Give two differential diagnoses?
3. What is the treatment of this condition?

---

Answer on page 101