

Incidence of Vitamin D Deficiency in Patients with Type II Diabetes Mellitus and its Relation to the Severity of Retinopathy

Abdulla Almoosa, MD* Seemantini Ayachit, MBBS, DOMS, PGDM-HM*
Abdulaziz Aldoseri, MD** Wael Wagih, FRCSEd***

Objective: To evaluate the prevalence of vitamin D deficiency (VDD) in patients with type II diabetes mellitus (DM) and evaluate the relationship between deficiency of vitamin D and severity of diabetic retinopathy (DR).

Design: A Prospective Observational Study.

Setting: Ophthalmology Department, King Hamad University Hospital, Bahrain.

Method: Three hundred patients were included in the study. The inclusion criterion was patients with type II DM and the exclusion criterion was patients who were on vitamin D supplementation. DR was classified clinically into three groups: No Diabetic Retinopathy (NDR), Non-Proliferative Diabetic Retinopathy (NPDR) and Proliferative Diabetic Retinopathy (PDR). Level of vitamin D was classified according to serum 25-hydroxyvitamin D (25(OH)D) into three groups: normal, insufficient and deficient.

Result: Low level of serum 25(OH)D was commonly found in type II DM patients, with a prevalence of 92%. There was a significant decrease in 25(OH)D concentrations with the advanced stages of DR. Patients with PDR had significantly lower serum 25(OH)D concentrations compared to other groups.

Conclusion: VDD was commonly found in type II DM patients. Lower serum 25(OH)D levels were associated with more severe DR. In our study, all of the PDR patients had VDD and the lowest serum 25(OH)D levels (<20 ng/ml).

Bahrain Med Bull 2019; 41(4): 238 - 240

The prevalence of DM is increasing worldwide, especially in the Middle Eastern region which has the highest prevalence of type II DM (10.9%)^{1,2}. DM, in the long-term, results in multi-system microvascular complications including diabetic retinopathy (DR) which is the leading cause of preventable blindness in the middle-aged population³. Several risk factors might increase the severity of DR including poor compliance and long duration of DM^{4,5}. Prevalence of vitamin D deficiency (VDD) is very high worldwide⁶. Indoor living conditions with minimal exposure to sunlight are the main causes of the increasing number of patients with VDD in the Middle East^{7,8}.

Deficiency of vitamin D was considered to play a role in the development of cancers, infections, autoimmune diseases, diabetes and its complications⁹. Vitamin D receptors are present in large numbers in the retina, and VDD is thought to play an important role in the pathogenesis and development of DR¹⁰⁻¹². Nevertheless, there is inadequate evidence to associate the degree of VDD and the severity of DR.

The aim of this study is to evaluate the prevalence of VDD among type II DM patients and to evaluate its relationship with the severity of DR.

METHOD

Three hundred patients with type II DM were included in the study. Patients who received vitamin D supplements were excluded from the study. Dilated fundus examination, fundus photography and optical coherence topography of macula were performed. DR was classified according to The International Clinical Disease Severity Scale: No Diabetic Retinopathy (NDR), Non-Proliferative Diabetic Retinopathy (NPDR) and Proliferative Diabetic Retinopathy (PDR)¹³. Serum 25(OH)D was measured for all patients and vitamin D level was classified according to the Centers for Disease Control and Prevention: Normal (>30 ng/ml), Insufficient (20-30 ng/ml) and Deficient (<20 ng/ml)¹⁴. P-value was calculated using Chi-square test. The strength of the association was calculated using Pearson Correlation Coefficient (R).

RESULT

A total of 300 patients with type II DM were included in the study; 150 (50%) patients had NDR, 99 (33%) patients had NPDR and 51 (17%) patients had PDR. The majority of type II DM patients had reduced levels of vitamin D (25(OH)D

* Registrar
** Senior House Officer
*** Consultant Ophthalmologist
Department of Ophthalmology
King Hamad University Hospital
Kingdom of Bahrain
E-mail: Abdulla.almoosa@khuh.org.bh

<30ng/ml) with a prevalence of 92%. Mean serum 25(OH)D concentration in type II DM patients was 17.2 ng/ml. Serum concentration of 25(OH)D was inversely associated with the severity of DR (P-value = <0.000005, R=-0.27). The PDR group had significantly lower serum 25(OH)D concentrations compared to NDR and NPDR groups, see table 1. Mean serum 25(OH)D concentration in PDR patients was 12.6 ng/ml. Fifty-seven (9%) patients of NDR group, forty-six (15.3%) of NPDR group and 27 patients (9%) of PDR group had vitamin D deficiency, see figure 1.

Table 1: Serum 25-Hydroxyvitamin D (25[OH]D) Levels among Diabetic Retinopathy Patients

	Normal Serum 25(OH)D (>30 ng/ml)	Serum 25(OH)D Insufficiency (20-30 ng/ml)	Serum 25(OH)D Deficiency (<20 ng/ml)	Total
NDR	15 (5%)	48 (16%)	87 (29%)	150 (50%)
NPDR	7 (2.3%)	30 (10%)	62 (20.7%)	99 (33%)
PDR	0	0	51 (17%)	51 (17%)
Total	22 (7.3%)	78 (26%)	200 (66.7%)	300 (100%)

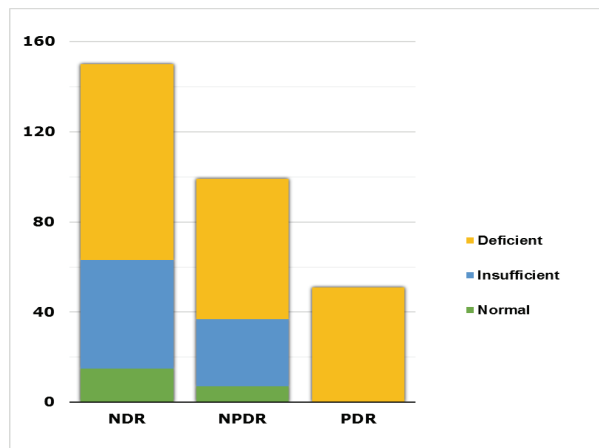


Figure 1: Serum 25-Hydroxyvitamin D (25[OH]D) Levels in Patients Grouped into Different Diabetic Retinopathy Stages

DISCUSSION

DM is a high-prevalence disorder affecting more than 300 million individuals worldwide; the Middle East region is considered to be the highest in adult DM patients with a prevalence of 10.9%^{1,2}. In addition to affecting the quality of life, it has multi-system long-term complications which have to be monitored and managed accordingly. These complications are divided into microvascular and macrovascular, with the former being more prevalent⁴. DR is the most common microvascular complication and is the leading cause of blindness in middle-aged population worldwide³. Several risk factors have been implicated such as poor glycemic control, long duration of diabetes, obesity and hypertension⁵.

Vitamin D, also known as cholecalciferol, is a vital metabolite in different body organs. Its metabolized form, 25-hydroxyvitamin D (25(OH)D), is necessary for the regulation of endocrine and

autocrine systems. The human body can obtain vitamin D from two main sources, either internal production via cutaneous synthesis after exposure to ultraviolet light or external via dietary or supplementation. Vitamin D deficiency has a high prevalence worldwide. Multi-factorial conditions can affect vitamin D concentration, the most common of which among Middle Eastern population is the lack of vitamin D rich food and inadequate sunlight exposure due to indoor activities and cultural clothing customs⁸. Different levels of 25(OH)D have been quoted, and no common definitions were established for a definite level. According to the Centers for Disease Control and Prevention, a 25(OH)D mean serum level of <20 ng/mL is generally acknowledged as vitamin D deficiency, a mean serum level of 20–30 ng/mL as insufficient, >30 ng/mL as inadequate and >75 ng/mL as sufficient^{14,15}.

Multiple diseases are linked to VDD, such as cancers, infections, autoimmune diseases, diabetes mellitus and its complications⁹. Several studies to evaluate the relation between VDD and the existence of DR found controversial results^{11,12}. Vitamin D receptors are found in multiple body tissues, including the pancreatic cells in which vitamin D could alter the body insulin secretion mechanism and insulin body sensitivity as well. In addition, retinal cells have shown to have a large number of vitamin D receptors¹⁰. Different mechanisms may explain the role of vitamin D deficiency in the pathogenesis of diabetic retinopathy additional to its effect on insulin secretion and sensitivity. Vitamin D has an inhibitory effect on inflammatory responses by regulating different inflammatory markers such as B and T lymphocytes, C-reactive protein, TNF- α , interleukin 10 and interleukin 4 which could prevent and treat the complications of DM¹⁶. Moreover, vitamin D plays an important role in preventing vascular smooth muscle cells proliferation and angiogenesis¹⁶. Therefore, a decrease in vitamin D concentrations could reduce these anti-inflammatory effects and lead to the development and progression of DR as it is characterized by vascular changes including neovascularization secondary to vascular endothelial growth factor release by ischemic retina¹³.

We found a close relationship between VDD and DR and confirmed the results of some previous studies^{6,12,15}. It showed an inverse association between vitamin 25(OH)D concentration and the severity of DR. Hence, PDR group showed the lowest concentration of 25(OH)D than other groups. These findings do not ascertain that treating VDD can stop the DR from progression or whether vitamin D supplementation may prevent DR formation.

CONCLUSION

Low serum 25(OH)D level (insufficient or deficient) was common in type II DM patients with a prevalence of 92%. In our study, vitamin D level was significantly inversely related with severity of DR. Patients with VDD should be screened and treated as needed to prevent progression of the disease to proliferative stage. Whether vitamin D supplementation may treat or prevent DR in patient with type II DM remains to be investigated.

Author Contribution: All authors share equal effort

contribution towards (1) substantial contribution to conception and design, acquisition, analysis and interpretation of data; (2) drafting the article and revising it critically for important intellectual content; and (3) final approval of manuscript version to be published. Yes.

Potential Conflicts of Interest: None.

Competing Interest: None.

Sponsorship: None.

Acceptance Date: 17 June 2019.

Ethical Approval: Approved by the Research and Ethics Committee, King Hamad University Hospital, Bahrain.

REFERENCES

1. Sherwin R, Jastreboff AM. Year in Diabetes 2012: The Diabetes Tsunami. *J Clin Endocrinol Metab* 2012; 97:4293–4301.
2. Kharroubi AT, Darwish HM. Diabetes Mellitus: The Epidemic of the Century. *World J Diabetes* 2015; 6(6): 850–867.
3. Klein BE. Overview of Epidemiologic Studies of Diabetic Retinopathy. *Ophthalmic Epidemiol* 2007; 14(4):179-83.
4. Papatheodorou K, Banach M, Bekiari E, et al. Complications of Diabetes 2017. *J Diabetes Res* 2018; 2018: 3086167.
5. Stratton IM, Kohner EM, Aldington SJ, et al. UKPDS50: Risk Factors for Incidence and Progression of Retinopathy in Type II Diabetes Over 6 Years from Diagnosis. *Diabetologia* 2001; 44:156–163.
6. Alcubierre N, Valls J, Rubinat E, et al. Vitamin D Deficiency is associated with the Presence and Severity of Diabetic Retinopathy in Type 2 Diabetes Mellitus. *Journal of Diabetes Research* 2015; 2015:374178.
7. Naem Z. Vitamin D Deficiency- An Ignored Epidemic. *Int J Health Sci (Qassim)* 2010; 4(1): V–VI.
8. Bassil D, Rahme M, Hoteit M, et al. Hypovitaminosis D in the Middle East and North Africa. *Dermatoendocrinol* 2013; 5(2):274-98.
9. Holick MF. Vitamin D Deficiency. *N Engl J Med* 2007; 357:266–281.
10. Taverna MJ, Selam JL, Slama G. Association between a Protein Polymorphism in the Start Codon of the Vitamin D Receptor Gene and Severe Diabetic Retinopathy in C-Peptide-Negative Type 1 Diabetes. *J Clin Endocrinol Metab* 2005; 90:4803–4808.
11. Bonakdaran S, Shoeibi N. Is There Any Correlation between Vitamin D Insufficiency and Diabetic Retinopathy? *Int J Ophthalmol* 2015; 8:326–331.
12. Patrick PA, Visintainer PF, Shi Q, et al. Vitamin D and Retinopathy in Adults with Diabetes Mellitus. *Arch Ophthalmol* 2012; 130:756–760.
13. Wilkinson CP, Ferris FL, Klein RE, et al. Proposed International Clinical Diabetic Retinopathy and Diabetic Macular Edema Disease Severity Scales. *Ophthalmology* 2003; 110:1677–1682.
14. The Centers for Disease Control and Prevention. Fat-Soluble Vitamins & Micronutrients: Vitamin D. https://www.cdc.gov/nutritionreport/99-02/pdf/nr_ch2b.pdf / Accessed on 02 June 2019.
15. Luo BA, Gao F, Qin LL. The Association between Vitamin D Deficiency and Diabetic Retinopathy in Type 2 Diabetes: A Meta-Analysis of Observational Studies. *Nutrients* 2017; 9(3). pii: E307.
16. Fan L, Zhang Y, Zhu J, et al. Association of Vitamin D Deficiency with Diabetic Peripheral Neuropathy and Diabetic Nephropathy in Tianjin, China. *Asia Pac J Clin Nutr* 2018; 27(3):599-606.