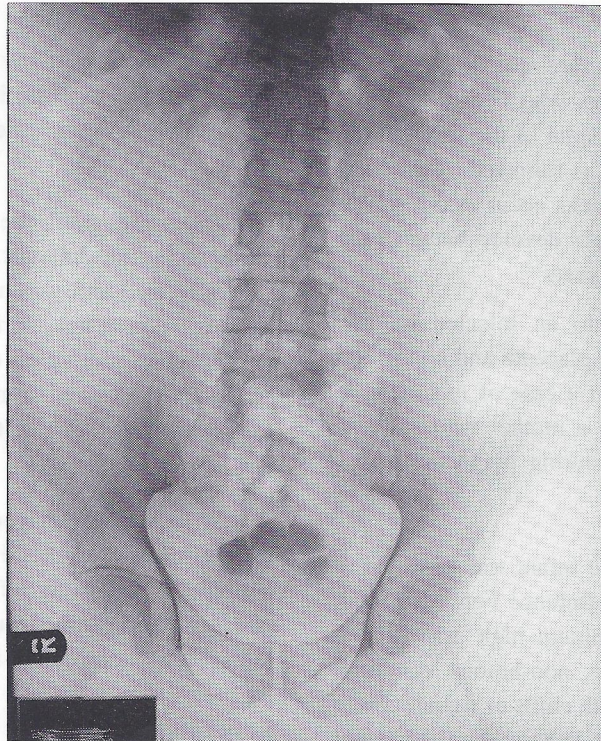


# MEDICAL QUIZ

Najeeb Jamsheer, MD

Abdominal radiograph of a 68 year old Bahraini gentleman who has long standing history of poor voiding stream, repeated lower urinary tract infection and intermittent retention of urine.



- Q 1. What is the main radiographic abnormality ?
- Q 2. What is the main primary aetiology responsible for the radiographic abnormality ?
- Q 3. Mention three other possible aetiologies/predisposing factors in different age and sex groups, responsible for this abnormality ?

Answers on page 107