

Medical Quiz

Igor Tagasovski, MD*

A 40-year-old man (cardiologist) as part of inspecting the new ultrasound cardiac probe, he try it on himself (4 chamber view, while standing) and immediately he noticed some abnormality. He reported to the ER for quick workup. On examination, he was alert and hemodynamically stable. His vital signs were a regular heart rate 84 beat/min, BP 130/80 mmHg and T 36.6°C. No pathological finding was observed in the examination of any organ system, there were no hearth murmurs. The Chest X ray and ECG revealed no abnormalities. All lab work was normal. Look at the figure below and answer the following questions.

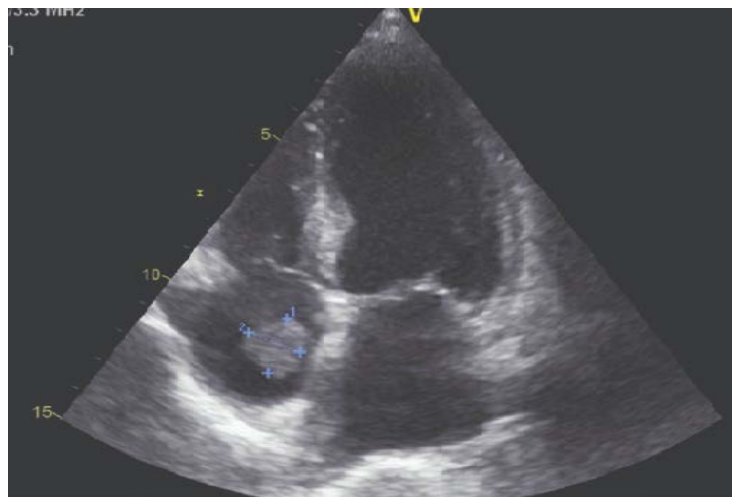


Figure 1

- Q1. Describe the finding in the figure.
- Q2. What are the possible differential diagnoses?
- Q3. What is the recommended treatment for this condition?

Answers on page 978

* Cardiologist
Affidea-Sv. Rok, Zagreb, Croatia
E-mail: i.tagasovski@hotmail.com