

## Congenital Chloride Diarrhea in Two Yemeni Siblings

Hadhami Ben Turkia, MD, PhD\* Yomna Hesham Ahmed, MB, BCH, BAO\*\*  
Mohamed Abdullah Bucheeri, MB, BCH, BAO\*\* Hala AbdelMoeman Eldssouky, MD, MSc, PhD\*

**Congenital chloride diarrhea (CCD) is a rare disorder caused by a genetic defect in the chloride/bicarbonate exchange in the ileum and colon which manifests as a neonatal secretory diarrhea with electrolytes imbalance and predispose to long-term complications. The disease is highly prevalent in the Arabian Peninsula.**

**We report two Yemeni siblings with CCD. Family history was significant with two deaths at 3 months of age. Polyhydramnios, antenatal dilated bowels, prematurity and neonatal onset of watery diarrhea were found in both infants. As a result of inadequate electrolytes supplementation, both children had growth development retardation and one developed a chronic renal disease at 6 years of age.**

*Bahrain Med Bull 2018; 40(3): 178 - 180*

Congenital chloride diarrhea (CCD, OMIM#214700) is secretory diarrhea due to damaging mutations in the SLC26A3 gene that codes for the chloride/bicarbonate exchanger. The dysfunction results in excessive chloride fecal loss<sup>1</sup>.

Severe dehydration along with electrolyte imbalance is usually lethal during the first weeks or months of life in untreated children. Long-term complications include growth and mental retardation and chronic renal disease<sup>2,3</sup>.

The world's highest incidences have been reported in Finland and in the Arabian Peninsula, particularly Kuwait and Saudi Arabia, due to founder effect mutations and a high rate of consanguinity<sup>4</sup>. To our knowledge, no CCD was described in the Yemeni population.

The aim of this presentation is to report the evaluation of the clinical features and long-term complications of CCD in two patients.

### THE CASE

The patients are products of a consanguineous marriage. The mother is a G8P5D3. She had one stillbirth and two girls who died at 3 months of age in Yemen due to diarrhea.

The boy was seen the first time at 6 years of age. He was born prematurely in Yemen after a pregnancy complicated with severe polyhydramnios. He was admitted several times during his first three years of life for diarrhea and dehydration. After that, he had not had any sicknesses apart from passing watery stools approximately 10 times per day; he never received any oral rehydration solution. He achieved his normal milestones, his weight and height were below the 3<sup>rd</sup> centile and no signs of dehydration were noted.

The blood investigations revealed normal sodium, hypokaliemia 3 mmol/l, hypochloremia 95 mmol/l (NV: 102-112). Other investigations were as follows: normal venous blood gas; pH 7.43, PCO<sub>2</sub> 37 mmHg, HCO<sub>3</sub> 25mmol/l, Urea 7.9 mmol/l (NV: 2.5-6), creatinine: 43 mcmmol/l (NV: 17-70), uric acid 463 mcmmol/l (NV 119-416). Urine analysis was normal.

US revealed kidneys of average size with poor corticomedullary differentiation. The child refused to be compliant with electrolytes supplementation.

His sister was born in Bahrain at 36 weeks of gestation with a birth weight of 2.520 kg. Prenatal ultrasound revealed evidence of severe polyhydramnios and multiple moderately dilated bowel loops at 31 weeks.

Neonatal examination at birth was unremarkable except for mild abdominal distension. The first stools passed were watery and greenish in color. She continued to have watery stools thereafter with a frequency of 6 times per day and remained in the NICU for a total of 23 days, due to electrolytes imbalance.

The patient's stool pH was 5 (normal 4.7-7.5) and stool reducing substances were negative. Fecal electrolytes at 2 weeks of age revealed sodium level of 11 mmol/24h (NV: 0.5-12.5), potassium 8 mmol/24h (NV: 3.1-19.5) and high chloride 4.6 mmol/24h (NV: 0.5-3).

Serum aldosterone performed at one week of life was high, 336 ng/dl (NV: 5-132).

She was discharged on KCl and amino acid formula. The proton pump inhibitors prescribed for 3 months was ineffective.

She was admitted several times within two years for exacerbation of her diarrhea and hypokalemia concomitant

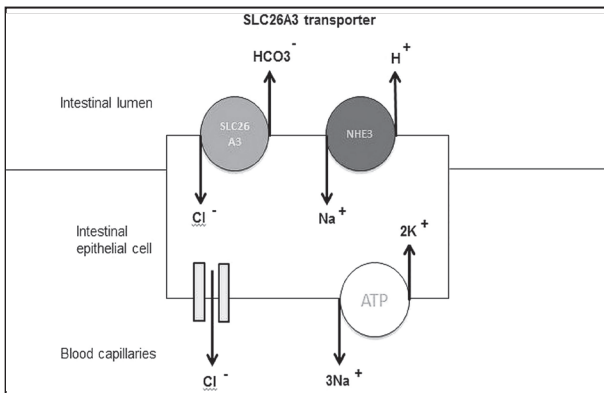
---

\* Consultant Pediatrician  
\*\* Intern  
Department of Pediatrics  
King Hamad University Hospital  
Kingdom of Bahrain  
E-mail: hadhami.benturkia@khuh.org.bh

to febrile illness. Her blood-gas revealed an intermittently hypochloremic metabolic alkalosis. The patient is currently two and a half years old, and her weight and height are below the 3<sup>rd</sup> centile. She has normal development and her renal function is normal.

## DISCUSSION

Congenital chloride diarrhea (CCD) is a rare autosomal recessive disease caused by mutations in SLC26A3 gene encoding a Cl<sup>-</sup>/HCO<sub>3</sub><sup>-</sup> exchanger. This results in defective intestinal absorption of chloride and secretion of HCO<sub>3</sub><sup>-</sup>. The coupled Na<sup>+</sup>/H<sup>+</sup> exchanger (NHE2) is defective, leading to intestinal loss of both NaCl and fluid, and watery Cl-rich diarrhea, see figure 1<sup>1,5</sup>.



**Figure 1: SLC26A3 Coupled with NHE3 Exchanger in an Intestinal Epithelial Cell**

In untreated patients, hypochloremia, hyponatremia, and dehydration result in activation of the renin-angiotensin system. Hyperaldosteronism results in Na<sup>+</sup> reabsorption and depletion of K<sup>+</sup> <sup>6</sup>.

The SLC26A3 gene is also expressed in the sweat glands, epididymis and kidneys; therefore, the CCD also manifests as high sweat chloride, male infertility and chronic kidney disease<sup>7</sup>.

The high incidence among Kuwaiti and Saudi Arabian population (1:5500 live births) is due to the high rate of consanguinity and a founder effect of the nonsense mutation G187X, observed in 94% of Arabic patients<sup>4,8</sup>.

To our knowledge, this is the first reported CDD in a Yemenite population where a high rate of consanguineous marriages is common. The family history of fetal loss, maternal hypertension, prematurity, and IUGR are frequently observed<sup>9</sup>.

Maternal polyhydramnios and distended fetal hypochoic bowels are frequent antenatal findings that may indicate intrauterine diarrhea. These abnormalities were found in 12 Kuwaiti patients reported by Elrefae et al<sup>9</sup>.

Colombani et al reported that MRI in addition to ultrasound findings may help to distinguish CDD from bowel obstruction and cystic fibrosis<sup>10,11</sup>. As observed in our two patients, the secretory diarrhea begins typically within the first few days of

life resulting in dehydration, hyponatremia, hypochloremia and hypokalemia<sup>3</sup>.

Some infants remain undiagnosed for several months with severe exacerbations concomitant to febrile illness. The mean age at diagnosis was 10 months in ten Saudi Arabian patients in one study<sup>12</sup>. The diagnosis might be delayed in neonates as watery diarrhea can be mistaken for urine and hypochloremic hypokalemic metabolic alkalosis could mimic Bartter Syndrome<sup>13</sup>.

The diagnosis of CCD is confirmed by high fecal chloride concentration of >90 mmol/l (>60mmol/l in newborns) after correction of the fluid and electrolyte depletion<sup>3</sup>. Severely dehydrated infants could show a lower fecal chloride content. The elevated ratio of stool Chloride/Na + K is more valuable in these cases<sup>9</sup>.

The fecal chloride concentration in mmol/24h, was high in our patient. The acidic stool, the absence of reducing substances and the normal fecal sodium concentration excluded other causes of secretory diarrhea; hyperaldosteronism supported the diagnosis of CDD in our patient. Based on the genetic background of the family, the diagnosis could be easily confirmed by a targeted sequencing for the founder Arabic mutation of SLC26A3 gene (G187X)<sup>4,8</sup>. However, the test is not available in Bahrain.

Our first patient, who never received any salt substitution, developed stage II nephropathy at the age of 6 years. This demonstrated that the renal injury was clearly associated with inadequate salt substitution especially during the first months or years of life which caused chronic hypovolemia and salt depletion resulting in activation of the renin-aldosterone system<sup>14</sup>.

In a study, chronic kidney disease was reported in 28% of Finnish patients<sup>14</sup>. The renal injury could be seen as juxtaglomerular hyperplasia, hyalinized glomeruli, nephrocalcinosis and vascular changes. Nephrocalcinosis occurs as a result of metabolic alkalosis leading to alkaline urine which predisposes to deposition of calcium phosphate and oxalate<sup>14</sup>.

The treatment is based on lifelong supplementation with sodium and potassium chloride solutions providing 4 mmol/kg/day of chloride. Such treatment will not treat diarrhea but will prevent its secondary effects. Short courses of cholestyramine may be temporally beneficial to reduce the diarrhea<sup>15</sup>.

Salt substitution should be titrated to achieve normal electrolyte and acid-base status and adequate excretion of Cl<sup>-</sup> into the urine, >30 mmol/L. Plasma renin activity and serum aldosterone should be monitored twice a year and glomerular filtration rate every 2–3 years<sup>5</sup>.

## CONCLUSION

**CCD is a severe chronic disease which might lead to acute and long-term complications. Early diagnosis and optimal electrolyte supplementation could prevent long-term complications. Genetic study and counseling could avoid recurrence in high risk populations.**

**Author Contribution:** All authors share equal effort contribution towards (1) substantial contribution to conception and design, acquisition, analysis and interpretation of data; (2) drafting the article and revising it critically for important intellectual content; and (3) final approval of manuscript version to be published. Yes.

**Potential Conflicts of Interest:** None.

**Competing Interest:** None.

**Sponsorship:** None.

**Acceptance Date:** 5 July 2018.

**Ethical Approval:** Approved by the Research and Ethics Committee, King Hamad University Hospital, Bahrain.

## REFERENCES

1. Moseley RH, Hoglund P, Wu GD, et al. Down-Regulated in Adenoma Gene Encodes a Chloride Transporter Defective in Congenital Chloride Diarrhea. *Am J Physiol* 1999; 276: G185–92.
2. Holmberg C, Perheentupa J, Launiala K, et al. Congenital Chloride Diarrhea; Clinical Analysis of 21 Finnish Patients. *Arch Dis Child* 1977; 52:255–267.
3. Holmberg C. Congenital Chloride Diarrhoea. *Clin Gastroenterol* 1986; 15(3):583-602.
4. Hoglund P, Auranen M, Socha J, et al. Genetic Background of Congenital Chloride Diarrhea in High-Incidence Populations: Finland, Poland, and Saudi Arabia and Kuwait. *Am J Hum Genet* 1998; 63: 760–8.
5. Wedenoja S, Höglund P, Holmberg C. Review Article: The Clinical Management of Congenital Chloride Diarrhoea. *Aliment Pharmacol Ther.* 2010; 15; 31(4):477-85.
6. Holmberg C. Congenital Chloride Diarrhoea. *Clin Gastroenterol* 1986; 15(3):583-602.
7. Abou Ziki MD, Verjee MA. Rare Mutation in the SLC26A3 Transporter Causes Life-Long Diarrhoea with Metabolic Alkalosis. *BMJ Case Rep* 2015; 7; 2015.
8. Lechner S, et al. Significance of Molecular Testing for Congenital Chloride Diarrhea. *J Pediatr Gastroenterol Nutr* 2011; 53(1):48-54.
9. Elrefae F, Elhassanien AF, Alghiaty HA. Congenital Chloride Diarrhea: A Review of Twelve Arabian Children. *Clin Exp Gastroenterol* 2013; 5(6):71-5.
10. Lundkvist K, Ewald, V, Lindgren PG. Congenital Chloride Diarrhea: A Prenatal Differential Diagnosis of Small Bowel Atresia. *Acta Pediatr* 1996; 53(3):295–298.
11. Kawamura T, Nishiguchi T. Congenital Chloride Diarrhea (CCD): A Case Report of CCD Suspected by Prenatal Ultrasonography and Magnetic Resonance Imaging (MRI). *Am J Case Rep* 2017; 24(18):707-713.
12. Kagalwalla AF. Congenital Chloride Diarrhea. A Study in Arab Children. *Clin Gastroenterol* 1994; 19(1):36-40.
13. Saneian H, Bahraminia E. Congenital Chloride Diarrhea Misdiagnosed as Pseudo-Bartter Syndrome. *J Res Med Sci* 2013; 18:822–4.
14. Wedenoja S, Ormälä T, Berg UB, et al. The Impact of Sodium Chloride and Volume Depletion in the Chronic Kidney Disease of Congenital Chloride Diarrhea. *Kidney Int* 2008; 74(8):1085-93.
15. Hihnala S, Höglund P, Lammi L, et al. Long-Term Clinical Outcome in Patients with Congenital Chloride Diarrhea. *J Pediatr Gastroenterol Nutr* 2006; 42(4):369-75.