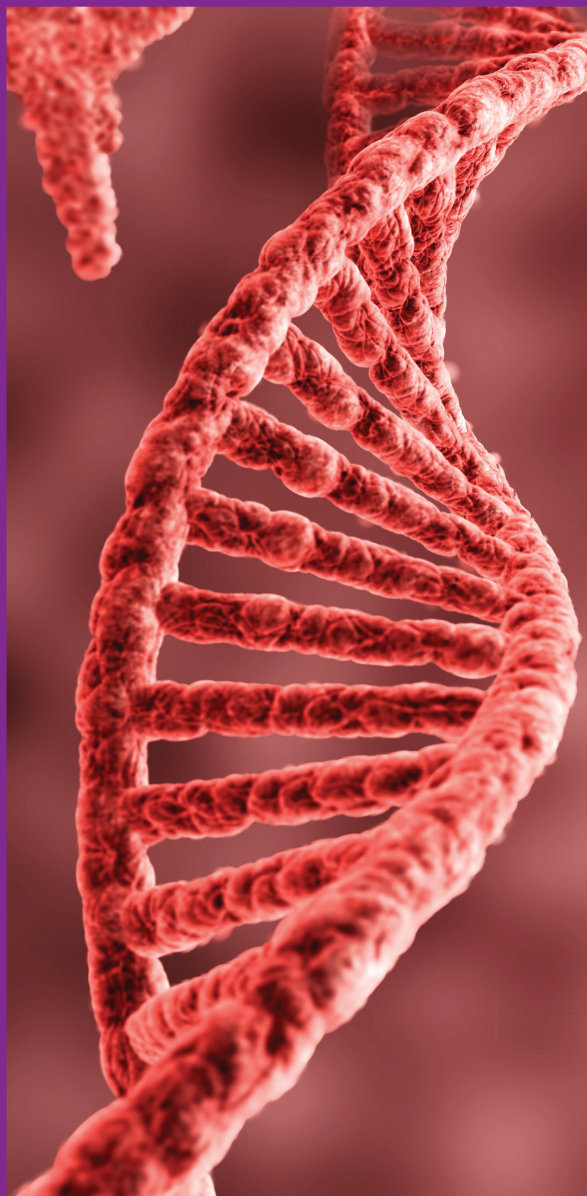




BAHRAIN MEDICAL BULLETIN



ORIGINAL

The Role of Lipid Profile and Intraocular Pressure Lowering Medications in Patients Diagnosed with Primary Open Angle Glaucoma

Ahmed Asal, Ali Alsada, Ahmed Ali, Muhammed Abdulnoor, Hawra Shakeeb

The Patterns of Juvenile Idiopathic Arthritis

Youssef Ali Mohamad Alqahtani

Necrotizing Fasciitis: Biochemical Markers and Prediction of Mortality

Jaffar AlKhuzai, Mariam AlKooheji, Huda AlHajari

Echo and Abdominal Ultrasound Findings among Type 1 DM (T1DM) Adolescent in Correlation with HBA1C Level and Duration of Diabetes

Mohammad Ahmad Awwad Alqahtani, Abdullah Othman, Mohammed Ghathradi, Safar Al-Shahrani, Maali Melha, Sahar Al-Shehri

Cutaneous Manifestations among Hospitalized Systemic Lupus Erythematosus Patients

Yahya Argobi, Saeed Asiri, Bader Asiri, Khalid Fayi, Khaled Albejadi, Sara Soliman, Mansour Somaity

Angiographic Pattern and Final Outcome of Peripheral Vascular Disease

Ameera Ali Kahalafallah, Sherif Khashaba

Frequency of Renal Colic during the Month of Ramadan

Mahmood N. Mustafa, Abdullah J. Al-Omran, Ayman A. Raees

Epidemiology of Congenital Heart Disease in the Kingdom of Bahrain

Abhinav Agarwal, Suad R. Al Amer, Neale Nicola Kalis

Trends of Peritoneal Dialysis

Rani AlAgha, Asma AlQaseer, Noof Sami Aljirdabi, Abdulraqueeb Abdo, Ali Hasan AlAradi, Hasan Alderazi

Incidental Thyroid Carcinoma in Patients Presumably Operated for Benign Thyroid Diseases

Mohammed AbdulHussain Mhammed, Reem Jameel Ahmed

MEDICAL QUIZ

Saeed Alhindi

EDUCATION-FAMILY PHYSICIAN CORNER

Meigs Syndrome, A Case Report of Fibrothecoma Presented with Torsion

Shazia Tabassum

CASE PRESENTATION

Tooth Avulsion: Etiology and Management

Abrar Al Bin Ali, Fahad Al Qooz, Omar Saleh Mustafa

Abdominal Cerebrospinal Fluid Pseudocyst Formation: A Rare Intra-Abdominal Complication Following Ventriculoperitoneal Shunt

Tareq Hamed Al Taei, Abdulaziz Hajjaj Al Thinayyan, Sarah Ali Al Mail

Managing Intractable Acanthamoeba Keratitis with Collagen Cross-linking

Hala Ahmed Khalil, Wael Wagih

Advantages and Complications of Laparoscopic Adjustable Gastric Banding

Abdullah Dalboh

Spontaneously Expelled Giant Submandibular Stone

Hasan Alansari, Fahad Bedawi, Waleed Janahi

Idiopathic Complete Heart Block with Early Post Pacemaker Lead Failure in a Child

Arun Bableshwar, Suad Al Amer, Mohammad Amin, Neale Nicola Kalis

Acute Hypercalcemia Coincidental with Intracapsular Parathyroid Hemorrhage

Wiam Ibrahim Hussein, Suzanne Abbas

The Rare Coexistence of Systemic Lupus Erythematosus and Myasthenia Gravis in a 17-Year-Old Female

Ali Alsada, Basem Mustafa

Topical Steroids Induced Adrenal Insufficiency

Hajer Abdullah Alahmadi, Rola Alsulaiti, Jehan Abdulla

Hypoglycemia with Severe Lactic Acidosis

Hessa Al Banki, Jehan Abdulla

TALENT IN MEDICINE

1. Beware Corona!
 2. Even This Will Pass Away!
- Anil Kumar Chawla*



Volume 42 Number 3
SEPTEMBER 2020

<http://www.bahrainmedicalbulletin.com>

ISSN 1012-8298
US NLM ID 8503052