

## **Papillary Carcinoma of Thyroglossal Duct Cyst**

Khalid Al-Sindi, FRCPath\* Fayek Al Hilli, PhD\*\* Veena Nagaraj, MD\*\*\*  
Tariq Hameed, FRCSI\*\*\*\*

**Background:** Carcinoma arising from thyroglossal duct cyst (TGDC) is rare and account for 1 – 2 % of all excised cysts. It is debatable the origin of these tumours whether primarily arising from the TGDC or from metastasis from the thyroid gland. Papillary carcinoma is the most common encountered histological type but the diagnosis usually obtained postoperatively.

**Objective:** The aim of this study is to highlight this rare condition and to discuss the origin of these tumours. The preoperative diagnostic technique, histological criteria for diagnosis and treatment modalities were highlighted.

**Design:** Retrospective study.

**Setting:** Pathology Departments, Military Hospital and Salmaniya Medical Complex, Bahrain.

**Method:** Patients with TGDC papillary carcinoma who have been diagnosed postoperatively on histological examination after simple Sistrunk's operation during the study period from January 2002 to December 2008 were followed up for six and two years respectively. Patients' characteristics, clinical presentations and outcomes were reviewed.

**Result:** Two patients were encountered during the study period. Both presented with classical features of congenital midline thyroglossal duct cyst. The first patient had a localised tumour and was free of tumour recurrence for 6 years postoperatively. The second patient's tumor spread to surrounding tissue and lymph nodes, which necessitated aggressive surgery.

**Conclusion:** Papillary Carcinoma of the TGDC is a rare entity, it is usually a localised disease which has excellent prognosis after simple surgery in most cases. We present two cases of carcinoma of TGDC diagnosed postoperatively after simple Sistrunk's operation; one case had no recurrence and the other had widespread dissemination, which necessitated aggressive surgery. The histological diagnostic criteria of these tumours, their origin from the duct or the main gland were reviewed with treatment modalities.

*Bahrain Med Bull 2008; 30(3):*

---

\* Consultant Pathologist  
Bahrain Defence Force Royal Medical Services

\*\* Consultant Pathologist

Salmaniya Medical Complex  
Kingdom of Bahrain  
\*\*\* Resident Pathologist  
\*\*\*\*Consultant General Surgeon  
Bahrain Defence Force Royal Medical Services  
Kingdom of Bahrain

Thyroglossal duct cyst (TGDC) is the most common congenital anomaly of the thyroid gland. These cysts are usually asymptomatic but become clinically presentable whenever they develop complication such as infection, erosion of the hyoid bone, thyroid tissue ectopia and development of thyroid carcinoma. Thyroid carcinoma is diagnosed in approximately 1-2% of thyroglossal duct remnants and papillary carcinoma is the commonest<sup>1</sup>. The diagnosis is often established postoperatively at histopathological examination and this becomes a challenging surprise to the surgeons especially in patients with no proper preoperative investigation to rule out the presence of a similar lesion in the main thyroid gland. In some studies, 11.4% of patients with TGDC carcinoma harbour malignant foci in their thyroid gland at the time of diagnosis<sup>2,3</sup>. There is no consensus of opinion concerning the management of TGDC carcinoma, especially the role of total thyroidectomy and postoperative adjuvant therapy<sup>4</sup>.

The aim of this paper is to present two cases of TGDC papillary carcinomas diagnosed postoperatively after simple Sistrunk's operation and discuss histological diagnostic criteria of these tumours, their origin in view of the simultaneous occurrence of similar lesion in the main gland and review treatment modalities.

## **METHOD**

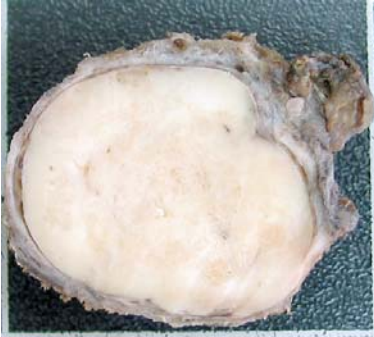Patients with TGDC papillary carcinoma who have been diagnosed postoperatively on histological examination after simple Sistrunk's operation during the study period from January 2002 to December 2008 were followed up for six and two years respectively. Patients' characteristics, clinical presentations and outcomes were reviewed.

## **RESULT**

### **Case One**

Nineteen years old Bahraini male student presented in January 2001 with central neck, firm, non-tender mass of two months duration which did not increase in size. There was also weight loss but no shortness of breath, voice change or dysphagia. Examination showed a 7x5 cm midline cystic swelling with smooth border which moved with swallowing and protrusion of tongue. His thyroid function tests and all other laboratory results were within normal limits. Neck CT showed well defined midline cystic lesion with solid calcified area extending anteriorly as well as posteriorly to the hyoid bone. Both thyroid lobes were normal and there was no lymphadenopathy. Sistrunk's procedure was performed and TGDC measuring 5x3x1 cm was dissected and excised from behind

the hyoid bone which histologically showed papillary thyroid carcinoma (Figure1). He was followed every 6 months and for 6 years with no sign of local recurrence and his thyroid function remained at euthyroid levels.

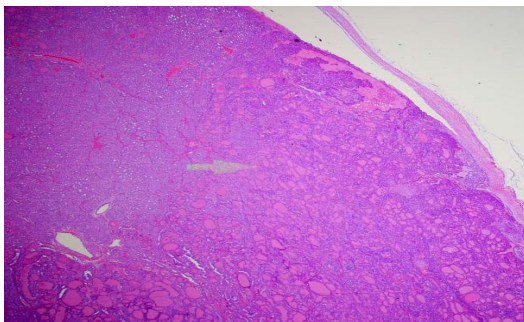


**Figure 1: The Excised Thyroglossal Cyst is Lined by Thin and Intact Wall. The Lumen is Entirely Filled by a Firmly Adherent Soft, Solid, Homogenous Creamy Content**

## Case Two

Thirty-three years old Bahraini female presented in July 2006 with anterior cervical midline swelling, which was there since childhood. It was not painful but she has noticed that it was increasing in size during pregnancy and wanted it removed for a cosmetic reason. There was no significant past medical or family history.

Examination showed anterior cervical midline swelling measuring 3x2cm, moving with both deglutition and protrusion of the tongue. She had no palpable cervical lymph nodes and her thyroid gland was not enlarged. Her vital signs, systemic examination, and all laboratory investigations were normal. A preoperative clinical diagnosis of TGDC was made, and substantiated by a favourable ultrasound examination. The cyst wall was thin and intact and the lumen was filled entirely with firmly adherent soft homogenous creamy content. No gross calcification was noted. Histologically, the solid intracystic mass was papillary carcinoma with predominant follicular growth pattern (Figure 2).



## **Figure 2: Histopathologic Examination: Solid Intra-cystic Mass Formed by Invasive, Papillary Carcinoma with Predominant Follicular Growth Pattern**

The cyst wall showed foci of tumour microinvasion but the outer ‘circumferential’ surgical margin was free. Several foci of lymphovascular invasions were noted together with metastatic deposits seen in a small extra-capsular lymph node. Residual ciliated respiratory type cyst lining epithelium was found, but no paramural, non-neoplastic thyroidal tissue was seen. In view of this unsuspected neoplastic histological finding the patient was investigated for the possibility of having another similar lesion in the main thyroid gland. Accordingly, the postoperative thyroid ultrasonography showed small nodules in both thyroid lobes raising the possibility of metastatic deposits. In August 2006, she underwent total thyroidectomy including the removal of pyramidal lobe along with the remaining part of TGDC and regional perivascular lymph nodes dissection.

Histological examination of the second operation specimens revealed a focus of papillary carcinoma in the processus pyramidalis only. Both thyroid lobes were clear of tumour; however, they contained structures of struma nodosa macro-et microfollicularis. A single positive right sided cervical lymph node was also confirmed. A follow up session of radioiodine ablation was undertaken. In October 2006, routine ultrasound and radioisotope studies, showed 3x4cm localised residual regional tumour in the ventral cricoids cartilage associated with elevated human Thyroglobulin (hTg) marker positivity on radioiodine scan and FDG-PET CT. She subsequently underwent radical tumour resection, along with partial removal of the hyoid bone and functional bilateral neck dissection. Histologically, this showed papillary carcinoma with tumour infiltration of the surrounding connective tissue but all the retrieved 45 cervical lymph nodes were negative. The Patient was maintained on radioiodine ablation therapy with 3692 MBq (99, 8 mCi) Iod-131 p.o. On 11<sup>th</sup> October 2006, no hoarseness, dysphagia, xerostomia or hypoparathyroidism were present and the patient was clinically euthyroid under the substitution of levothyroxine 150 µg/day. The bi-annual regular oncologic follow-up for the last two years including physical examination, hTg tumour marker, thyroid hormone profile, blood profile, liver function, renal function, cervical ultrasound, F-18-FDG-PET/CT, whole body spiral CT proved complete disease remission.

## **DISCUSSION**

Malignant changes arising in TGDC are uncommon. Ninety-four percent of these are carcinomas, mostly papillary of thyroid gland origin (75-80%), different types of carcinomas including mixed papillary – follicular carcinoma (6.9%), squamous cell carcinoma (5.2%), follicular (1.7%) and adenocarcinoma (1.7%) were reported<sup>3</sup>. Others malignancies such as Hürthle cell carcinoma, malignant struma, epidermoid carcinoma and anaplastic carcinoma have been reported<sup>3</sup>. Both cases reported in the present study are of the papillary type.

The clinical presentation of TGDC carcinoma is usually asymptomatic and in most cases indistinguishable from benign cysts. Carcinoma may present with a rapidly enlarging

neck mass, but the same history can be elicited in patients with recent infection in a benign cyst<sup>5</sup>. Carcinoma within the TGDC is mostly seen in adults, but children are rarely affected, although the lesion is present since birth. In the present paper, one patient, 19 years old male, noticed the lesion only 2 months before clinical presentation while in the other; 33 years old women had the lesion since birth. This slow growing malignant tumour may progress for 20 years or more, and spreads infrequently to regional lymph nodes before it metastasises to distant sites such as lung, liver or bone<sup>5</sup>. Invasion into surrounding soft tissue is seen in 17% of TGDC carcinomas and metastatic disease is present in 1.3%, which is much lower than the rate of carcinoma arising in the thyroid gland<sup>6</sup>.

Most cases of TGDC, similar to the presented, the diagnosis of malignancy is overlooked clinically and its malignant nature is identified only at postoperative histological examination. Clinical correlation between change in size with time as an indicator of carcinoma is not a reliable finding; nevertheless, carcinoma should be suspected in any TGDC which is hard, fixed and irregular or has undergone a recent rapid change in size. The presence of cervical lymphadenopathy should also suggest malignancy, likewise, history of irradiation to the neck or mediastinum during childhood should be an alert<sup>2,7</sup>.

It has been found that around 11.4% of patients with TGDC carcinoma harbour malignant foci in their thyroid gland at the time of diagnosis<sup>2,8</sup>. Cases associated with co-existent neoplastic foci in the thyroid gland may represent metastasis from a primary carcinoma in the cyst, two independent multicentric primary carcinomas, or a primary thyroid carcinoma with metastasis to the TGDC<sup>7</sup>. The presence of papillary thyroid carcinoma separate from the main gland including that occurring in a TGDC raises the possibility of an occult primary carcinoma in the thyroid, and it is important to distinguish whether carcinoma in the thyroglossal remnants originated primarily in this ectopic tissue or represented metastasis from the thyroid gland. This may sound easy but in practice it is extremely difficult to determine which the primary tumour is and which the secondary site of extension or metastasis is. To our knowledge, there is no current known immunohistochemical marker to distinguish between papillary carcinoma of TGDC origin and that arising from the main gland. However, the frequent finding of normal thyroid follicles in association with carcinomas in thyroglossal duct cysts suggests that they arise primarily from the cysts. Most benign thyroglossal duct cysts contain microscopic foci of thyroid tissue which are presumably the source of carcinoma. However, the unequivocal histopathological diagnosis of a primary TGDC carcinoma should strictly fulfil two main diagnostic criteria; firstly: localization of the neoplasia in a clearly demonstrable TGDC with identifiable residual ductular epithelial lining and the presence of normal thyroid follicles in the wall of the cyst; and secondly: absence of carcinoma on histopathological examination of the main thyroid gland at time of diagnosis<sup>2</sup>. Accordingly, only case one in the present report, we were able to identify residual ductular lining and normal thyroid follicles in the wall and no extracystic lesion fulfil these criteria and can be regarded as a primary TGDC carcinoma. Nonetheless, the clinical history, in case two, of midline neck swelling movable with swallowing, present since birth, and the associated presence of residual cyst lining remnants would still support its thyroid origin. But, still it can be regarded as an expression of two foci.

In the present study, the preoperative diagnosis of both neck lesions was TGDC based on clinical presentation and examination. Both patients underwent Sistrunk's operation with no preoperative investigations apart from routine laboratory chemistry and haematology tests. The possibility of neoplasia either in the cyst or in the main thyroid gland was not considered and the incidental histological finding of papillary carcinoma was a surprise. It is clear from the progress of the lesion in case one, that the carcinoma was in its early evolution before any extracystic extension. Simple Sistrunk's procedure ensured total excision and good prognosis. But in case two, the lesion existed since childhood and enlarged with pregnancy indicating that the lesion may have existed (within the TGDC or the main thyroid gland). Case two underwent various lines of management which we feel could have been averted should an appropriate protocol of investigation is followed.

We recommend that all patients with midline neck swelling particularly those clinically diagnosed as thyroglossal duct cysts should undergo fine needle aspiration cytology (FNAC) or frozen section of the cyst. There are a number of advantages for the FNAC diagnosis; firstly, it is an inexpensive and rapid method of diagnosis. The cytology will establish the pathology of the lesion and in case of neoplasia it shows the behaviour and histological pattern. Secondly, it is an easy procedure which can be performed blindly or under ultrasonic guidance. Guided sampling has an advantage over the blind approach by targeting the solid area of such lesions, where the yield of malignant cells is much better and helps to raise the FNAC diagnostic rate to 53%<sup>4,9</sup>. Some studies recommend that carcinoma should be considered in thyroglossal duct cysts that have a dense or enhancing mural nodule or calcification or both by contrast-enhanced CT of the neck using 3 to 5mm thick contiguous axial sections, especially in those who have cervical lymphadenopathy<sup>10</sup>.

Frozen section also proved useful in establishing the nature of TGDC. Complete surgical specimen need to be submitted for paraffin embedded histological examination even if the frozen section fails to reveal carcinoma. Proper sampling of the paraffin embedded-tissue must be undertaken in alliance with the radiology and biochemical tumour markers to exclude any possible evidence of tumour extracystic extension.

TGDC carcinoma in general has a good prognosis with a rare tendency for metastasis and less than 2% 5-year-mortality rate (REF). However, the biologic behaviour of TGDC tumours is similar to their counterparts in the thyroid gland itself, namely tumour histologic subtype, presence of extra-cystic tumour extension, with or without concomitant thyroid and nodal metastasis<sup>11</sup>.

The surgical treatment for benign TGDC is the Sistrunk procedure, in which the cyst, the central portion of the hyoid bone, and the entire thyroglossal tract are removed. The management of malignant lesion in TGDC is controversial. Kristensen et al suggested that the Sistrunk procedure is appropriate if firstly, histologically normal thyroid follicles are found in the cyst wall; secondly, the tumour has not extended through the cyst wall; thirdly, the thyroid gland is normal; and fourthly, no lymph node involvement is evident<sup>12</sup>. This approach gives excellent results as recurrence rate after such simple

excision is low<sup>12</sup>. It is believed that thyroglossal duct could act as a natural conduit for spread of thyroid carcinoma; therefore the prognosis of carcinoma occurring within these cysts is even better than those of primary papillary carcinoma of the thyroid gland<sup>12</sup>. However, conservative, radical, or modified neck dissection should be considered in cases associated with lymphadenopathy<sup>7</sup>. Thus while the Kristensen approach is widely acceptable, a radical line is now recommended for patients with positive cervical nodes (as assessed clinically or by radioimaging) and this consists of the Sistrunk procedure, total thyroidectomy and lymphadenectomy (whether by “cherry-picking” or modified neck dissection) followed by radioiodine ablation and thyroid hormone substitution<sup>7,9,13,14</sup>. The value of total thyroidectomy is to ensure that any possible coexistent occult primary foci in the main gland are removed. Total thyroidectomy would allow for better long-term monitoring of thyroid function tests and of I<sup>131</sup> scintigraphy as well as I<sup>131</sup> ablation therapy. The prognosis of this radical approach is usually excellent. TGDC carcinoma usually has < 2% 5-year-mortality rate, but long term oncologic follow up is mandatory to endure early detection of tumour recurrence<sup>14</sup>.

## CONCLUSION

**We present two cases of carcinoma of TGDC diagnosed postoperatively after simple Sistrunk’s operation. The histological diagnostic criteria of these tumours, their origin from the duct or the main gland were reviewed with treatment modalities.**

## REFERENCES

1. Ostlie DJ, Burjonrappa SC, Snyder CL, et al. Thyroglossal Duct Infections and Surgical Outcomes. *J Pediatr Surg* 2004; 39: 396-9.
2. Weiss SD, Orlich CC. Primary Papillary Carcinoma of a Thyroglossal Duct Cyst: Report of a Case and Literature Review. *Br J Surg* 1991; 78: 87-9.
3. Kennedy TL, Whitaker M, Wadhi G. Thyroglossal Duct Carcinoma: a Rational Approach to Management. *Laryngoscope* 1998; 108: 1154-8.
4. Asakage T, Nara S, Yoshizumi T, et al. Thyroglossal Duct Carcinoma: A Case Report. *Japanese J Clinical Oncology* 1997; 27: 340-2.
5. Trail ML, Zeringue GP, Chicola JP. Carcinoma in the Thyroglossal Duct Remnants. *Laryngoscope* 1977; 87: 1685-91.
6. Branstetter BF, Weissman JL, Kennedy TL, et al. The CT Appearance of Thyroglossal Duct Carcinoma. *American Journal of Neuroradiology* 2000 21(8): 1547-50.
7. Lindstrom DR, Conley SF, Arvedson JC, et al. Anterior Lingual Thyroglossal Cyst: Antenatal Diagnosis, Management, and Long-term Outcome. *Int J Pediatr Otorhinolaryngol* 2003; 67: 1031-4.
8. Stevens R, Greene F, Rana A. Thyroglossal Duct Cyst or Something More? *Contemporary surgery* 2006; 62(12).
9. Yang YJ, Hagher S, Wanamaker JR, et al. Diagnosis of Papillary Carcinoma in Thyroglossal Duct Cyst by Fine Needle Aspiration Biopsy. *Arch Pathol Lab Med* 2000; 124: 139-42.

10. Walton BR, Koch KE. Presentation and Management of a Thyroglossal Duct Cyst with a Papillary Carcinoma. *South Med J* 1997; 90: 758-61.
11. Prakash C, Saharia N. Carcinoma Arising in Thyroglossal Duct Remnant: Case Reports and Review of the Literature. *British Journal of Surgery* 2005; 62: 689-91.
12. Kristensen S, Juula A, Moesner J. Thyroglossal Cyst Carcinoma. *J Laryngol Otol* 1984; 98: 1277-80.
13. Plaza CP, Lopez ME, Carrasco CE, et al. Management of Well Differentiated Thyroglossal Remnant Thyroid Carcinoma: Time to Close the Debate? Report of Five New Cases and Proposal of a Definitive Algorithm for Treatment. *Ann Surg Oncol* 2006; 13: 745-52.
14. Astle J, Dusikova J, Kraus J, et al. Coincidence of Thyroid Tumour and Thyroglossal Duct Remnants. *Tumor* 2003; 89: 314-20.