

## **Steal Syndrome Management with Saving Hemodialysis Access**

Mohammed A Saboor, MS\* GR Nair, MS,MCh\*\*  
Wadiea Yousif, FRCR\*\*\*

**Steal syndrome is one of the serious complications of hemodialysis access procedure. Ligation of the fistula with access loss was the obligatory treatment. Distal revascularization interval ligation (DRIL) is a recently introduced procedure for management of steal syndrome with preservation of the access.**

**Sixty-four years old female with chronic renal insufficiency developed steal syndrome after hemodialysis access creation. She underwent DRL with preservation of the access. Patient symptoms relieved immediately after the procedure. DRL procedure relieve symptoms of steal syndrome without jeopardizing the hemodialysis access.**

***Bahrain Med Bull 2004;26(4):***

Hemodialysis access creation is one of the most commonly performed operations in peripheral vascular surgery<sup>1</sup>. Minimal shunt volume flow rates in adult patients with antilogous shunts range between 300 and 500 ml /min are adequate for dialysis purposes and maintain the patency of the fistula<sup>2</sup>. With an inappropriately high shunt flow, cardiac complications from volume overload and dialysis access-associated steal syndrome may occur<sup>3</sup>. Hand ischemia due to arterial steal syndrome is an infrequent, but potentially serious complication of hemodialysis access procedure<sup>4</sup>. Several surgical options have been described for steal syndrome correction as ligation of the access and banding of the fistula. These procedures are associated with a certain incidence of access loss. Increased popularity of distal artery Ligation and revascularization as a new option for management of steal syndrome with preservation of the hemodialysis access is a challenge.

### **THE CASE**

Sixty-four years old woman with diabetes mellitus and chronic renal insufficiency, underwent a haemodialysis access creation in the form of left brachio-cephalic fistula 4 months ago. She presented to the vascular outpatient clinic complaining of pain in the left arm for one hour each time she starts dialysis. It begins by tingling and numbness in the fingers, which progress to dull aching pain extending to the forearm and associated with hand weakness. This type of pain is so severe that each time she asks to stop dialysis the

---

\* Chief Resident

\*\* Consultant Surgeon

Department of Surgery

\*\*\* Consultant Radiologist

Department of Radiology

Salmaniya Medical Complex

Kingdom of Bahrain

pain disappears within few minutes after cessation. On examination, the patient hand was pale and cool with delayed capillary refill. A thrill of the fistula was present in the graft, but the radial pulse was feeble. No significant paresthesia or weakness. Left upper limb angiography showed normal brachial artery, filling of the cephalic, subclavian and innominate veins and attenuated radial and ulnar arteries (Fig 1). Angiogram after A-V fistula compression showed well-delineated radial and ulnar arteries and good blood supply to the hand (Fig 2).

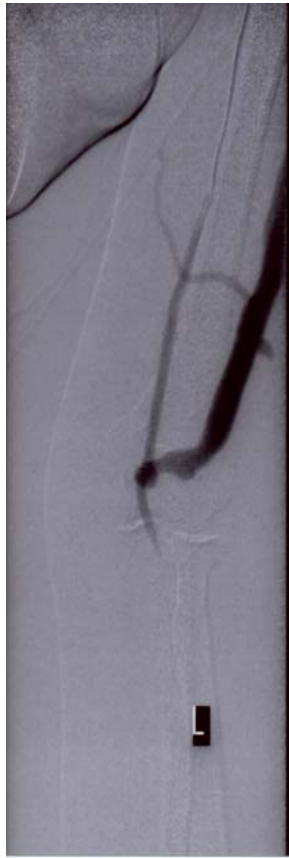

Fig 1. Left arm angiogram of steal syndrome showing diversion of blood to the AV fistula with attenuated distal vessels.

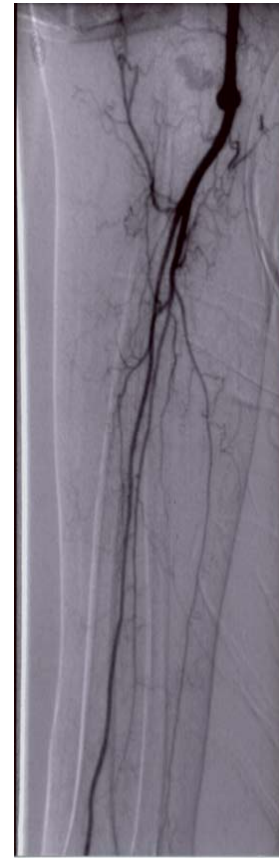

Fig 2. Angiogram of the same patient after AV-Fistula compression

The patient underwent exploration of the access (Fig 3). Distal vessels patency were confirmed by Fogarty catheter. Four to 7 mm tapered Polytetrafluoroethylene (ePTFE) graft originating from the brachial artery proximal to the access site anastomosed into the same artery distal to the access. The brachial artery between the source of fistula inflow and the distal anastomosis of the graft was divided and ligated (Fig 4). Access patency was assessed by the presence of thrill and bruit over the fistula and confirmed by doppler flow measurement. Post-operatively, radial pulse became palpable; the hand became warm and nearly normal capillary refill. Dialysis started two days after the procedure without pain or complaint. Doppler US, three weeks post-operative showed good flow in the radial artery (Fig 5).

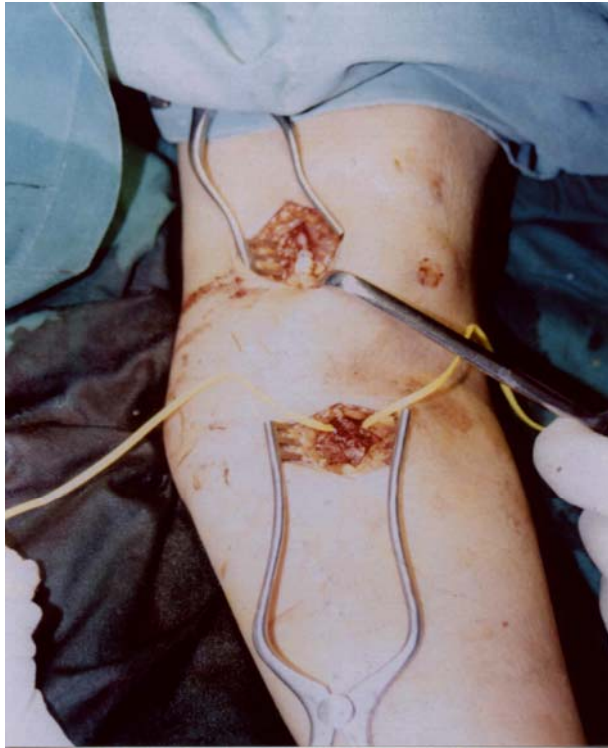

Fig 3. Surgical exploration of the AV-fistula and brachial A Proximal to fistula origin.

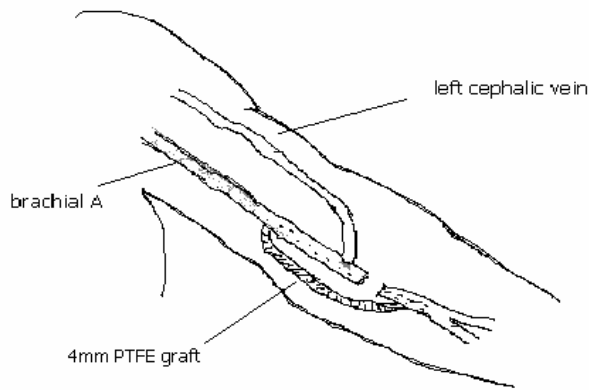


Fig 4. Diagram of the left arm brachiocephalic fistula, brachial artery bypass with PTFE graft and its interval ligation.

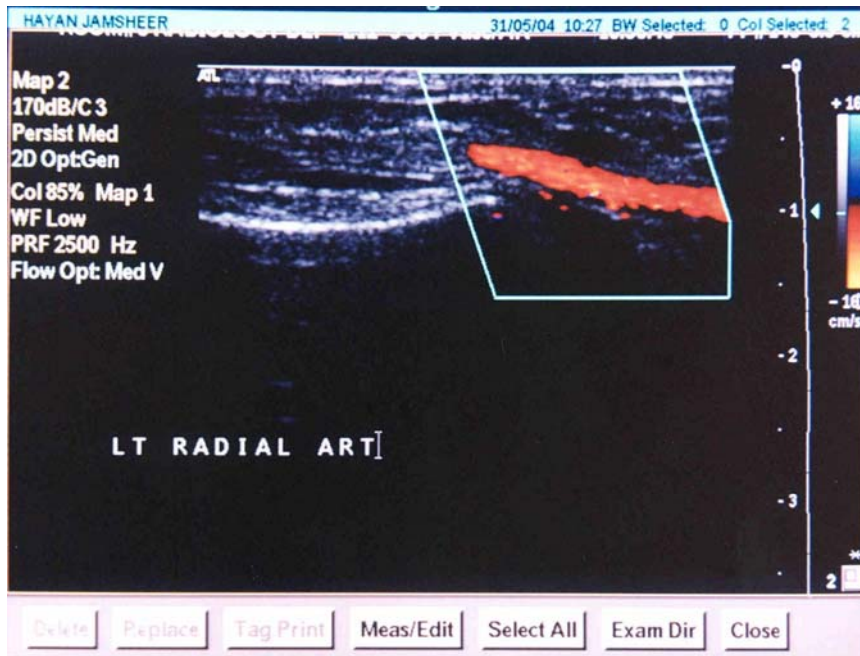


Fig 5. Post-operative colored Doppler showing good flow in the radial artery

## DICUSSION

Steal syndrome is diversion or “ steal ” of blood from the distal circulation. This creates a zone of arterial insufficiency in the tissue distal to the fistula, which manifested by pain, ischemic neuropathy, ulceration and gangrene<sup>5</sup>. Hand ischemia in patients with arteriovenous grafts (AVG) and arteriovenous Fistula (AVF) were 2.3% and 3.6%, respectively<sup>7</sup>. Access-induced ischemia occurs not only because of consuming the antigrade flow in the artery at the level of the fistula, but also steals a portion of the distal arterial collateral flow via retrograde flow from the native artery distal to the fistula origin<sup>8</sup>.

Peter et al, reported 14 patients of hand ischemia following hemodialysis access placement. Diabetes mellitus, hypertension and peripheral artery disease were found in the majority. Despite the common risk factors noted among their patients, they were unable to identify risk factors that predisposed these patients to develop hand ischemia<sup>7</sup>.

Symptomatic hemodialysis access-induced ischemia was treated with several operative techniques with varying degrees of satisfactory outcomes. The simplest operative approach is the arteriovenous access ligation. This technique lead to access loss and to continue renal replacement therapy; a new access route must be created. Banding of the fistula or the use of a tapered graft is another option designed to treat access-induced ischemia. It consists of narrowing of the inflow portion of the fistula with increasing fistula resistance. This will indirectly increase perfusion to the extremity distal to the access origin. In practice, there is difficulty in establishing the precise degree of narrowing required for elimination of the ischemia and allowing patent fistula<sup>9</sup>. Banding sufficient to alleviate steal, would be predicted to reduce fistula flow to the point of thrombosis<sup>10</sup>.

Distal revascularization interval ligation (DRIL) in treating access-induced ischemia was first described by Schanzer et al<sup>6</sup>. He used an autogenous vein graft bypass. He divided the brachial artery between the source of fistula inflow and the distal anastomosis of the graft. The bypass graft acts as a large arterial collateral which improves perfusion pressure in the arteries distal to the arteriovenous access. The interval ligation eliminate reversal flow from the distal arteries to access<sup>11</sup>. Despite their initial success with three cases, the technique was not widely adopted.

Schanzer et al and Haimov et al, subsequently reported their experience with a series of 23 patients underwent DRIL in 1996, they showed improvement in all the patients with bypass patency rate of 95.6%, at 2 years<sup>12</sup>. The largest reported experience with the DRIL procedures using reverse saphenous vein graft by Knox et al<sup>10</sup>. In that study, 47 of 52 patients (90%) showed immediate significant symptomatic improvement. Three patients needed access ligation due to inadequate resolution of symptoms. The failure possibly caused by concomitant small vessel disease. In three other patients, a re-DRIL was successfully performed after the first procedure failed because of graft thrombosis. The 48-month patency rate in this study is 80%. The main indication for DRIL procedure in the study group was rest pain with tissue loss. Only one patient (2%) underwent DRIL because of persistent pain during dialysis treatment similar to this case. Despite the high success rate of the procedure in relieving the ischemia and maintaining access patency, this technique still received little recognition.

In this case the main complaint was severe pain during dialysis, no rest pain. She underwent DRIL using PTFE graft for bypass. Patient symptoms relieved immediately and dialysis started two days after the procedure without complaint.

## **CONCLUSION**

**Distal Revascularization-interval ligation is the procedure of choice for Steal syndrome. It increases distal perfusion without jeopardizing the function of the hemodialysis access.**

## REFERENCES

1. Chazan JA, London MR, Pono LM. Long-term survival of vascular accesses in a large chronic hemodialysis population. *Nephron* 1995;69:228-33.
2. National Kidney Foundation. Dialysis Outcome Initiative. Clinical practice Guidelines for vascular access: update 2000. *Am J Kidney Dis* 2001;37(Suppl 1):s137-81.
3. Aschwanden M, Hess P, Labs K, et al. Dialysis access-associated steal syndrome: The intraoperative use of duplex ultrasound scan. *J Vasc Surg* 2003;37:211-3.
4. Kevin L, Greason, MD, Jay D, et al. Ischemic Monomelic Neuropathy, A Case Report and Literature Review. *J Vasc Surg* 1998;32:385-90.
5. DeCaprio JD, Valentine RJ, Kakish HB, et al. Steal syndrome complicating hemodialysis access. *Cardiovasc Surg* 1997;5:64.
6. Schanzer H, Skladany M, Haimov M. Treatment of angioaccess-induced ischemia by revascularization. *J Vasc Surg* 1992;16:861-4.
7. Peter H, Lin MD, Chen CMD, et al. Management of Hand Ischemia in Patients with Hemodialysis Access by Distal Arterial Ligation and Revascularization. *J Vasc Surg* 1999;33:481-8.
8. Wixon CL, Hughes JD, Mills JL Understanding strategies for the treatment of ischemic steal syndrome after hemodialysis access. *J Am Coll Surg* 2000;191:301-10.
9. Shaffer D. A prospective randomized trial of 6 mm versus 4-7 mm PTFE grafts for hemodialysis access in diabetic patients. In: Henry ML, Ferguson RM, eds. *Vascular Access for Hemodialysis V*. Chicago: Precept press, 1995.
10. Knox C, Berman S, Hughes D, et al. Distal revascularization-interval ligation: A durable and effective treatment for ischemic steal syndrome after hemodialysis access. *J Vasc Surg* 2002;36:250-5.
11. Haimov M, Schanzer H, Skladani M. Pathogenesis and management of upper-extremity ischemia following angio-access surgery. *Blood Purif* 1996;14:350-4.