

MEDICAL QUIZ

Mai Ebrahim Mattar, MD* Hakima Al Hashimi, FRCR,FFR(RCSI)*

A full term baby (see figures 1,2,3,4,5) was referred to the radiology department for further investigations. She was found to have some characteristic findings in her brain CT. The following images are representative of the diagnosis:

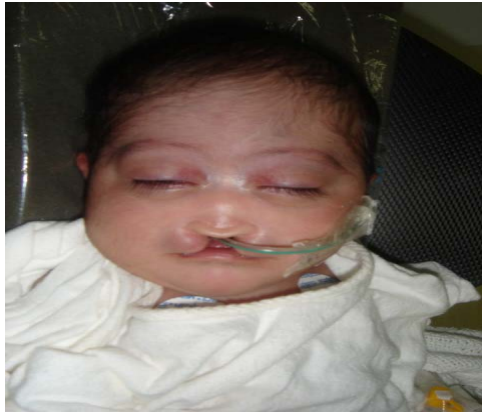

Figure 1

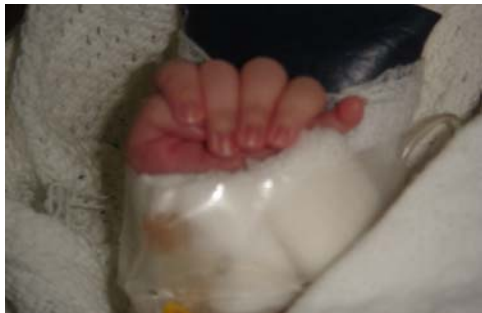

Figure 2

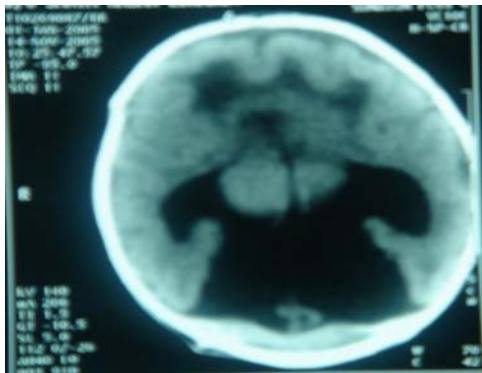


Figure 3

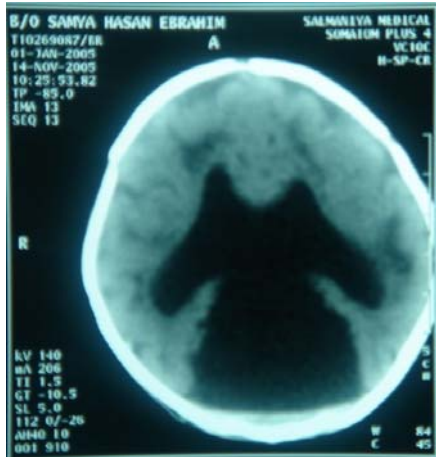

Figure 4

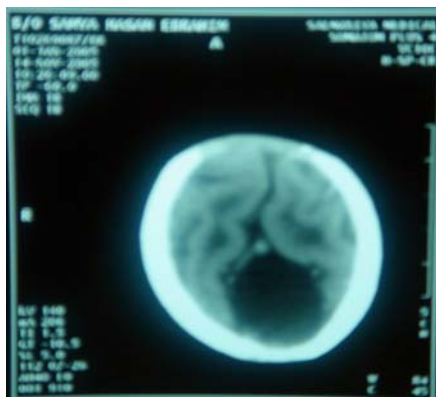


Figure 5

Q1. What is your diagnosis?