

## Bilateral Symmetrical Locking of the Metacarpophalangeal Joint: A Case Report

Bassam Dhaif, FRCSI, FRCS(Orth)\*, H Reda, FRCSI\*\*  
S O'flanagan, FRCSI,FRCS(Orth)\*\*\*

**Bilateral locking of the Metacarpophalangeal (MCP) joint is rare. The aetiology is usually caused by tethering of the radial collateral ligament on a prominent metacarpal head. We here describe a case report of a 44 year old lady with bilateral MCP locking. The surgical management is described.**

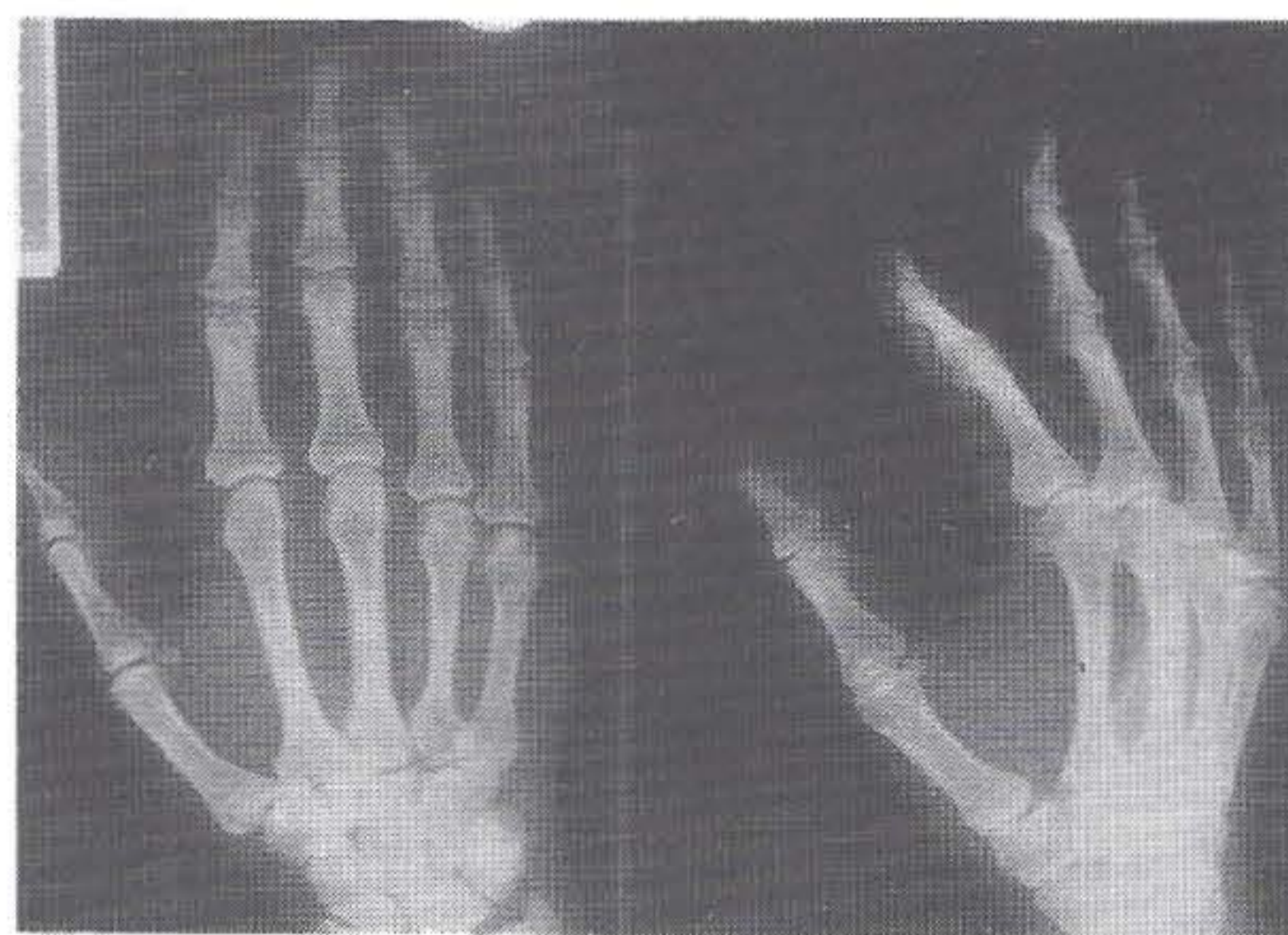*Bahrain Med Bull 1997;19(2): 54-55*

Locking of the metacarpophalangeal joint (MCP) is an uncommon condition and is recognised with increasing frequency since the earliest description by Langenskiold<sup>1</sup>. Bilateral locking of the MCP joint is rare. We here report a case of bilateral symmetrical locking.

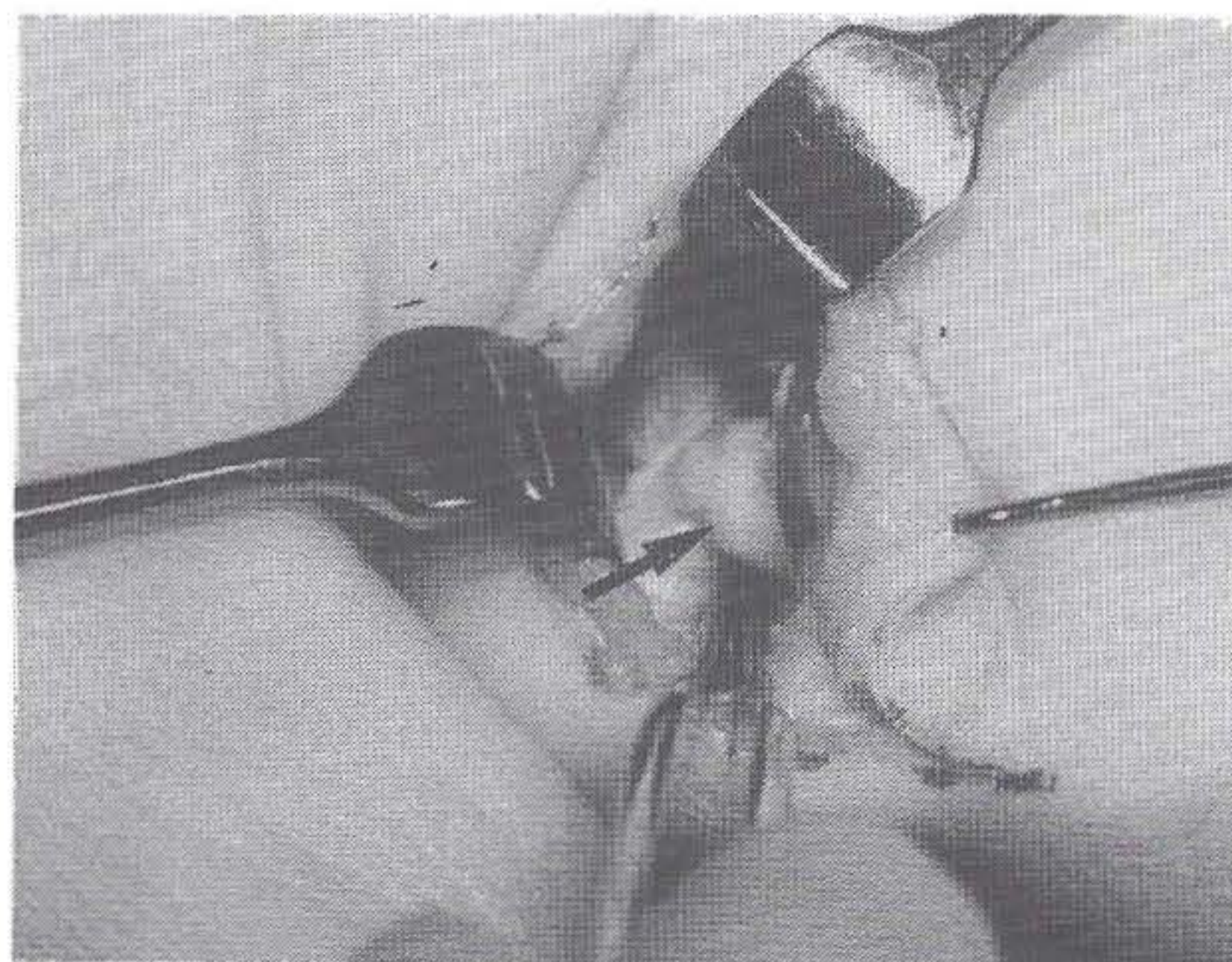
### THE CASE

An Irish woman aged 44 years presented with locking of the left index finger while carrying a heavy bag during shopping. She had a history of intermittent locking of both index fingers for 5 months. She was treated by manipulation under anaesthesia in another hospital which unlocked the MCP joint but it recurred and she presented to our unit. Examination revealed that the left index finger MCP joint was locked at 40° of flexion. The joint could be fully flexed but attempts of passive extension was not possible. Radiographs (Fig. 1) showed a very prominent condylar margin of the metacarpal head on the radial side.

Exploration of the MCP joint was carried out through a palmar incision. The accessory collateral ligament was tethered on the radial side of the metacarpal head. The ligament was released. The radial projection of the metacarpal head (Fig. 2) was resected and this eliminated the problem of locking and achieved full range of motion of the MCP joint. The accessory collateral ligament was reattached. Postoperatively, the patient regained full motion (Fig. 3). After 4 months, the patient presented with locking on the opposite side and underwent the same procedure.



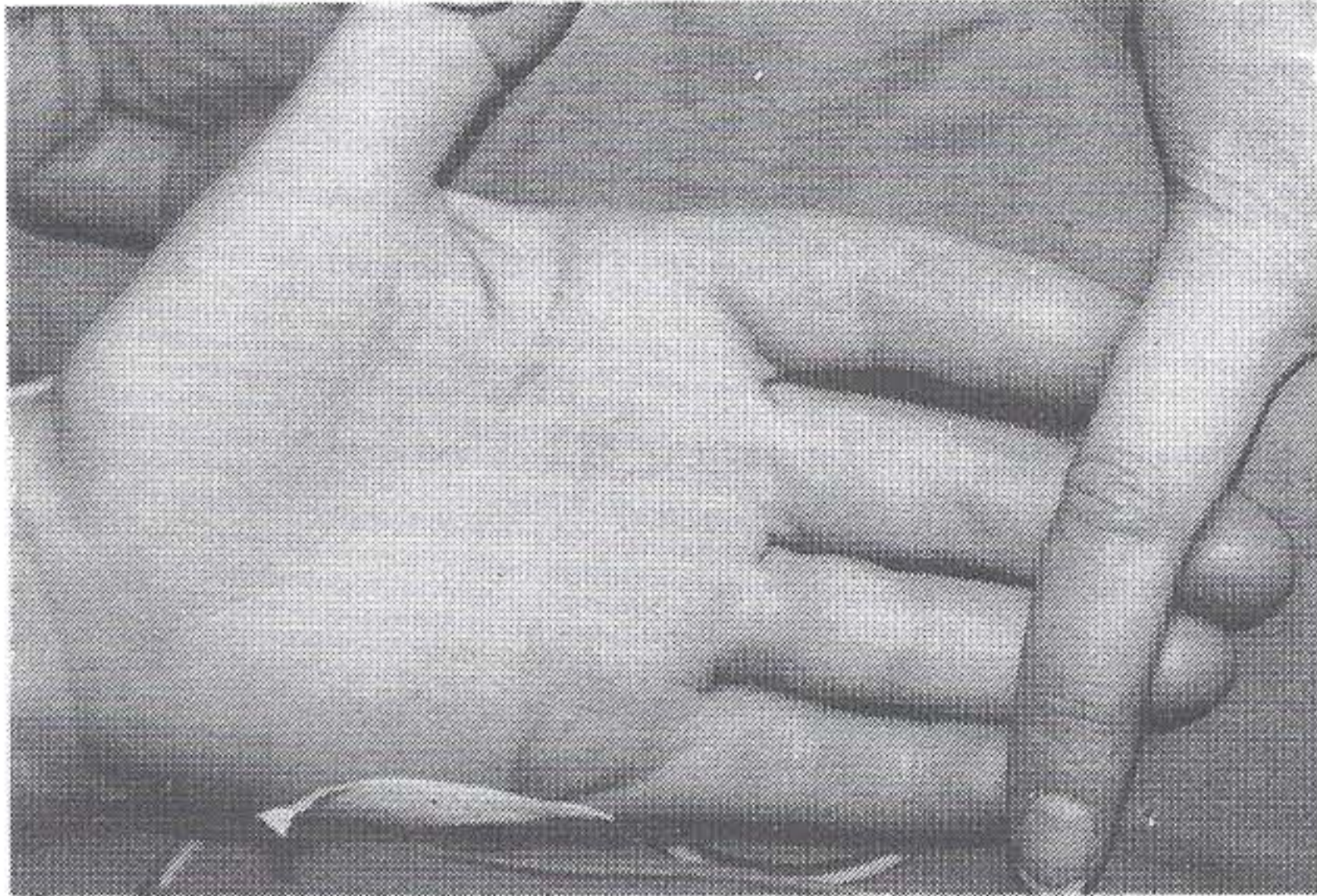
**Fig 1.** Anteroposterior and oblique radiographs of left hand showing a very prominent radial condylar margin of the metacarpal head of index finger.



**Fig 2.** Intraoperative photograph showing prominent radial projection of the metacarpal head.

\* Upper Limb Fellow  
\*\* Senior House Officer  
\*\*\* Consultant Orthopaedic Surgeon  
Cappagh Orthopaedic Hospital  
Finglas, Dublin 11  
Ireland





**Figure 3.** *Postoperatively full extension restored.*

## DISCUSSION

Locking of the MCP joint is an unusual clinical entity characterised by flexion deformity with loss of extension. It usually involves the index or middle finger. It can be caused by osseous and/or soft tissue abnormalities<sup>1-3</sup>. Rankin and Uwagie-Ero<sup>5</sup> reviewed 40 cases described in the literature including their four cases. All cases were unilateral. Bilateral locking of MCP joint is rare. In our patient the aetiology was tethering of the radial collateral ligament on a prominent metacarpal head. This is the mechanism described by Langenskiold<sup>1</sup>. Harvey<sup>2</sup>, classified MCP joint locking into two groups. The degenerative group which is seen in elderly patients is caused by catching of the volar plate on osteophytes on front of the metacarpal head. The other is the spontaneous group which is caused by tethering of the fan-shaped accessory collateral ligament on the bony prominence of the anterolateral aspect of the metacarpal head. The index finger is mainly involved in this group. Surgery is usually necessary to unlock the joint and to restore mobility<sup>2,5,6</sup>.

## CONCLUSION

**Bilateral locking of the MCP joint is rare. It is usually caused by prominent metacarpal head. Surgery is invariably needed to unlock the joint as was the case in our patient.**

## REFERENCES

1. Dibbell DG, Field JH. Locking Metacarpophalangeal Joint. *Plast Reconstr Surg* 1979;4:173.
2. Harvey FJ. Locking of the metacarpophalangeal joints. *J Bone Joint Surg* 1974;56B:156-9.
3. Honner R. Locking of metacarpophalangeal joint from a loose body. *J Bone Joint Surg* 1969;51B:479.
4. Langenskiold A. Habitual locking of a metacarpophalangeal caused by a collateral ligament, a rare cause of trigger finger. *Acta Chir Scand* 1949;99:43.
5. Rankin EA, Uwagie-Ero S. Locking of the metacarpophalangeal joint. *J Hand Surg* 1986;11A:868-71.
6. Posner MA, Langa V, Green SM. The locked metacarpophalangeal joint: Diagnosis and treatment. *J Hand Surg* 1986;11A:249-53.