

Prader-Willi Syndrome in Bahrain: Case Presentation

Abdul Hadi Khalil Ebrahim, MBChB, DCH, MRCP(1)*

Ibrahim Mannan Khan, MBChB, DCH**

Mohammed Sharif Anis-Alwogood, MBChB, MD (Paediatrics)***

A case of Prader-Willi syndrome (PWS) is described in a 6 year old Bahraini boy. He presented in the neonatal period with hypotonia and feeding problems. At 3 years of age he developed voracious appetite which led to obesity and psychiatric manifestations. Clinically he had dysmorphic features consistent with diagnosis of PWS. The diagnosis was confirmed by karyotyping and DNA analysis. Making early diagnosis of PWS is vital for: a) management of various manifestations, b) parental counselling and c) avoiding unnecessary investigations for simulating conditions.

Bahrain Med Bull 1999; 21(2): 64-66

PWS is a syndrome characterized by protean manifestations presenting early in life with new features as age advances. It is also known as Prader-Labhart-Willi syndrome when described first in 1956¹. The early fetal and neonatal signs are nonspecific, this include hypotonia, poor feeding and genital hypoplasia, changing later on to polyphagia, obesity, small hands and behavioral and psychiatric manifestations². The prevalence of PWS is one in 10,000 births, this figure now is increasing due to improved molecular genetic laboratory studies³. The diagnosis is confirmed by karyotyping and DNA analysis. In about 70% of the cases, it is caused by loss of a critical portion of the proximal part of the long arm of paternally derived chromosome 15 [del 15 (11q13)]^{4,5}. The remaining 30% of cases are of nondeletion, caused by inheritance of two maternal copies (two maternal copies of 15 q and absent paternal copy)⁶⁻⁸. We present our experience with a diagnosed patient suffering from PWS, followed by discussion.

THE CASE

A Bahraini male newborn delivered by an assisted breech after 36 weeks gestation to a 24 year old primigravida mother. Apgar scores were normal. Parents are not consanguineous. There was no history of neurological disorder on either side of the parents. Pregnancy was uncomplicated and according to the mother fetal movements were normal. At birth he appeared to be of normal morphology, apart from small hands (Fig 1). His growth parameters were as follows: Weight 2230 gm, length 47cm and head circumference 32.5 cm, corresponding to the 5th, 50th and 40th percentiles respectively. Physical examination showed normal morphology, except of small hands. He had profound hypotonia with diminished primitive reflexes. Testes were undescended (felt above inguinal ring), penis of normal size (20.5mm). Because of respiratory distress and prematurity, he underwent septic work-up and treated with

broad-spectrum antibiotics, intravenous glucose solution and 30% oxygen via head box. Five days later, because of poor sucking reflex, he was fed by nasogastric tube for two weeks. He started to suck the bottle and the breast very slowly. His blood culture was sterile. Blood glucose, urea, electrolyte and calcium were normal. Brain ultrasound was normal. Thyroid function test showed slightly elevated TSH (T3 and T4 were normal), for which he was treated with thyroxine for 3 months until a repeat test was reported normal.

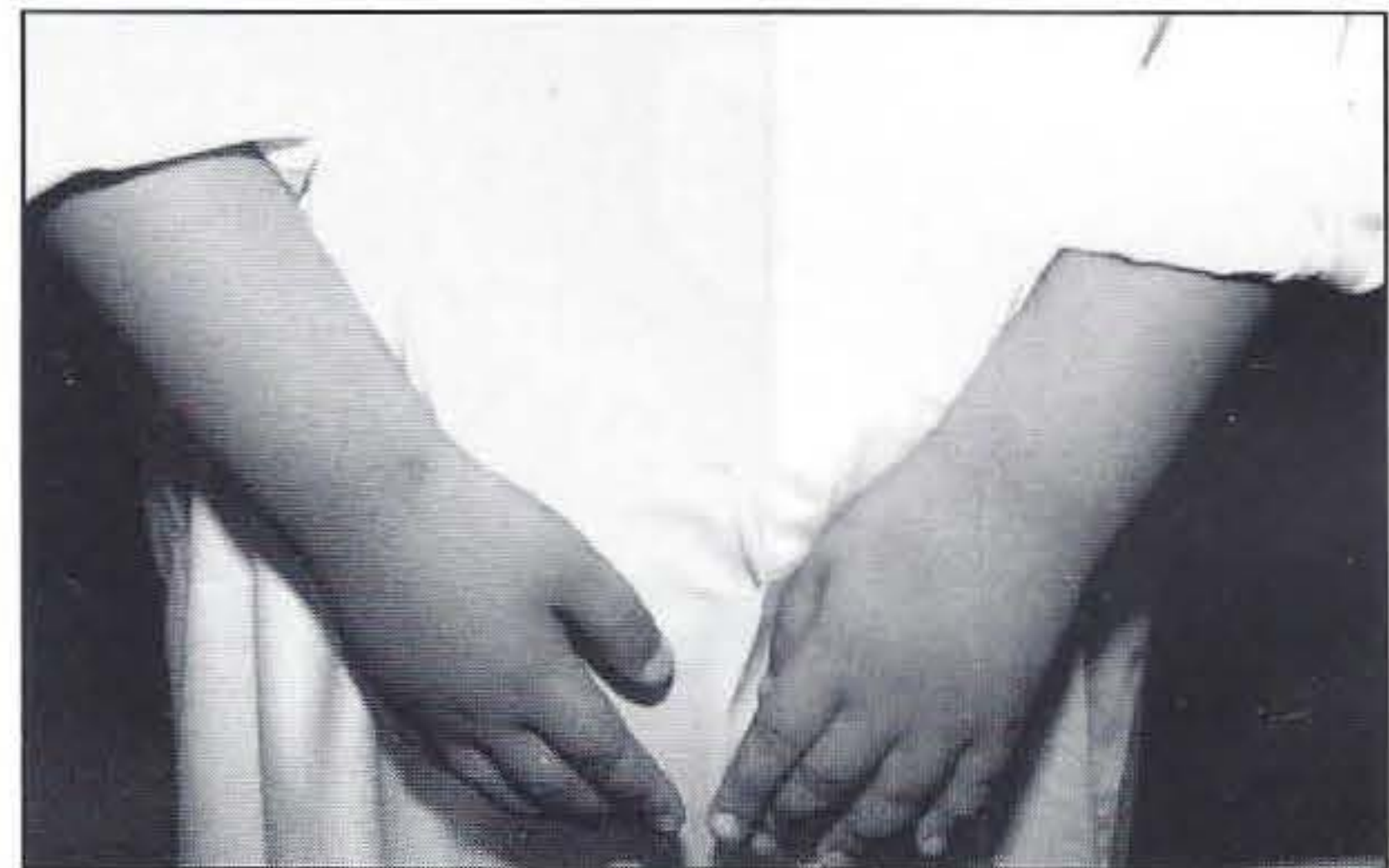

Figure 1: The hands of the patient showing small hands

Over the following months and first two years he showed marked developmental delay. Social smile was first noted at 6 months, attained head control at 10 months, rolled over at 14 months, sat unaided at 24 months and spoke meaningful polysyllables at 28 months. During the first year of life, he had feeding problem. His feeding time lasted more than half an hour, mostly by bottle, but also spoon feeding was used to expedite his feeding time. At 3 years of age he developed voracious appetite for milk and sugar containing food. He insisted on eating without restrictions, attempt to do so led frequently to tantrum and raging episodes. His morphological features changed to generalised obesity, with normal stature,

*Consultant Paediatrician & Neonatologist
Assistant Professor, Arabian Gulf University

** Chief Resident

*** Senior Resident,
Paediatrics Department
Salmaniyah Medical Complex
State of Bahrain

his head was dolichocephalic. The palpebral fissure was almond-shaped. The corners of the mouth were downward-turned (Fig 2). The hands were moderately small. The hair colour was fair, skin and eyes color were normal. The parents colour of the hair is black, the skin is light brown and the eyes were black. At 4 years and 3 months he weighed 31.1 kg (> 97th percentiles) and height was 108 cm (< 90th percentiles). A dietitian was consulted to control his obesity. Compliance with dietary restriction was poor. The obesity was investigated by brain and adrenal gland CT, fundic examination and ACTH stimulation test, all of which were normal and ruling out any hypothalamic-pituitary-adrenal pathology. He underwent orchidopexy. Chromosomal study and DNA analysis, performed overseas (JSPS Lab, Bewlay House, London, UK). It showed a normal boy with 46,xy karyotype. DNA analysis showed only maternal allele at 15q 11-13, typing the patient and his parents with polymorph markers on 15q confirmed that he had paternal deletion with GABRB3 and L-S I (D15S113).

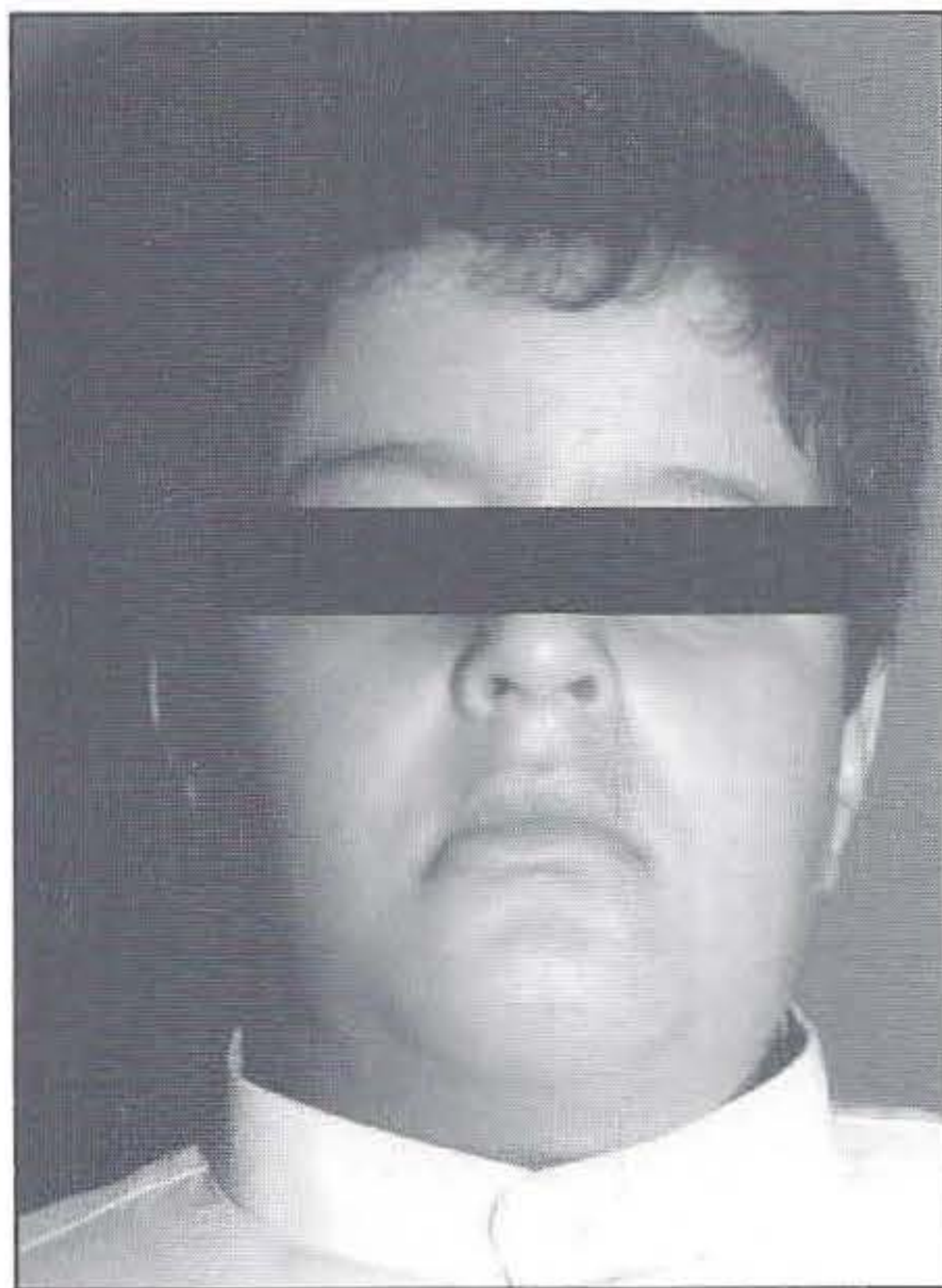


Figure 2: Profile of the patient showing facial features.

At 5 years of age, he remained polyphagic and moderately obese. He developed dental caries. Intelligence Quotient (IQ) was 60 on Griffith's Scale. His behavior was labile and frequently led to temper and aggressive episodes especially if prevented from eating certain food. At the age of 6 years he slept frequently during the day with inspiratory stridorous breathing (Pickwickian syndrome). During hospital stay to assess his problem, it was noted that he became hypoxaemic and hypercarbic. He underwent adenoidotonsillectomy to relieve his upper airway obstruction with little improvement. The family is trying to admit him in a special school for mentally handicapped children.

DISCUSSION

According to clinical features our case fulfill the criteria of Holmes et al⁹. In children over three the diagnosis is satisfied if there are 8 criteria, 5 of which must be major ones. Our patient presented with abnormal craniofacial and hands morphology, initial hypotonia, difficulty in feeding, later on

developed polyphagia and obesity. The diagnosis confirmed by karyotyping and DNA studies, which showed the usual (70%) abnormality of paternally deleted chromosome 15q^{4,5}. The etiology in the non-deleted cases (30%), the maternal disomy (with 2 maternal and no paternal allele) is presumably due to nondisjunction and duplication occurring early at the gametal stage^{3,8}. The mode of inheritance is sporadic in majority of cases³. However, some authorities claim that paternal exposure to hydrocarbons in the causation leading to deletion in PWS¹⁰. The delayed diagnosis in our case is not unusual. This is due to changing early signs and symptoms as children get older². The presence of upper airway obstruction and hyperventilation and obesity presented in our patient has been reported by others^{11,12}. A rare presentation, which did not present in our patient, is severe skin picking behavior⁹, this can be complicated by self-mutilation and extending this to the rectum resulting in lower gastrointestinal bleeding¹³. Our patient had dental caries reported by Dunn et al¹⁴. He also had faired hair color compared to his family member¹⁵. The presence of a common condition like nonspecific mental retardation, of about 3%¹⁶, should raise high index of suspicion for other condition simulating PWS.

The purpose of this presentation is to alert the clinicians not familiar with PWS in order to diagnose them early in life. This would be beneficial for: a) provision of multidisciplinary patient care, b) avoid unnecessary investigations (for other similar conditions) and c) provide a family counseling. It is noteworthy that this condition can be diagnosed antenatally using amniotic fluid¹⁷. To our knowledge this is the first case of PWS to be reported in Bahrain.

REFERENCES

1. Prader A, Labbart A, Willi H. Ein Syndrom von Adipositas, Kleinwuchs, Kryptorchismus un Oligophrenie nach myatonieartigem Zustand im Neugeborenenalter. Schweiz Med Wochenschr 1956;86:1260-1.
2. Cassidy SB. Prader-Willi syndrome. Curr Probl Pediatr 1984;14:155.
3. Donaldson MDC, Chu CE, Cooke A, et al. The Prader-Willi syndrome. Arch Dis Child 1994;70:58-63.
4. Ledbetter DH, Riccardi VM, Airhart SD, et al. Deletion of chromosome 15 as a cause of the Prader-Willi syndrome. N Engl J Med 1981;304:325-9.
5. Butler MG. Prader-Willi syndrome: Current understanding of cause and diagnosis. Am J Med Gent 1990;35:319-32.
6. Nicholls RD, Knoll JH, Butler MG, et al. Genetic imprinting suggested by maternal heterodisomy in nondeletion Prader-Willi syndrome. Nature 1989;16:281-5.
7. Robinson WP, Bottari A, Yagang X, et al. Clinical, molecular and cytogenetic survey of Prader-Willi syndrome patients. In: Cassidy SB, ed. Prader-Willi syndrome and Other Chromosome 15q Deletion Disorders. NATO ASI Series, Vol 61. Heidelberg, Germany: Springer-Verlag, 1992:53.
8. Robinson WP, Langlois S, Schuffenhauer S, et al. Cytogenetic and age dependent age factors associated with uniparental disomy 15. Prenat-Diagn 1996;9:837-44.
9. Holm VA, Cassidy CB, Merlin BG, et al. Prader-Willi syndrome: Consensus Diagnostic Criteria. Pediatrics 1993; 91:
10. Akefeldt A, Anvret M, Grandell U, et al. Parental exposure to hydrocarbons in Prader-Willi syndrome. Dev Med Child Neurol 1995;37: 1101-9.

11. Harris JC, Allen RP. Is excessive daytime sleepiness characteristic of Prader-Willi syndrome? The effect of weight change. *Arch Pediatr Adolesc Med.* 1996;150:1289-93.
12. Hertz G, Cataletto M, Feinsilver SH, et al. Developmental trends of sleep-disordered breathing in Prader-Willi syndrome: the role of obesity. *Am J Med Genet* 1995;56:188-90.
13. Bhargav SA, Putnam PE, Kocoshis SA, et al. Rectal bleeding in Prader-Willi syndrome. *Pediatrics* 1996;97: 265-7.
14. Dunn HG, Tze WJ, Alisharan RM, et al. Clinical experience with 23 cases of Prader-Willi syndrome. In: Holm VA, Sulzbacher SJ, Pipes P, eds. *Prader-Willi syndrome*. Baltimore: University Park Press, 1981:69-88.
15. Holm VA, Butler MG. Hypopigmentation is common feature of Prader-Lobhart-Willi syndrome. *Am J Genet* 1989; 45: 40-6.
16. Shonkoff JP. Mental Retardation, Children with Special Needs: An overview. In: Behrman RE, Kleigman RM, Nelson WE, et al. *Nelson Textbook of Pediatrics*, 14 edn. Philadelphia: WB Saunders Co,1992:95.
17. Toth-Fejel S, Magenis RE, Leff S, et al. Prenatal diagnosis of chromosome 15 abnormality in chromosome 15 in the Prader-Willi syndrome / Angelman syndrome region by traditional and molecular cytogenetics. *Am J Med Genet* 1995; 55: 444-52.