

MEDICAL QUIZ

Mona Al Mahroos, MD*

A seventy-year-old female presented with complaint of discomfort due to a growing mass in the external genitalia of about one year duration. She is diabetic and hypertensive, on oral hypoglycemic and anti-hypertensive agents. There was no regional lymphadenopathy. There were no other specific events in her past and family history. Laboratory investigations were all within normal range. The lesion and histology are shown below.

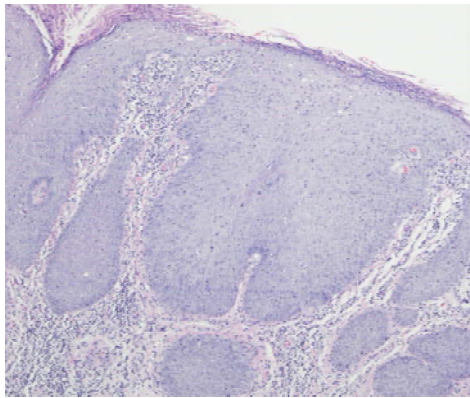


Figure 1

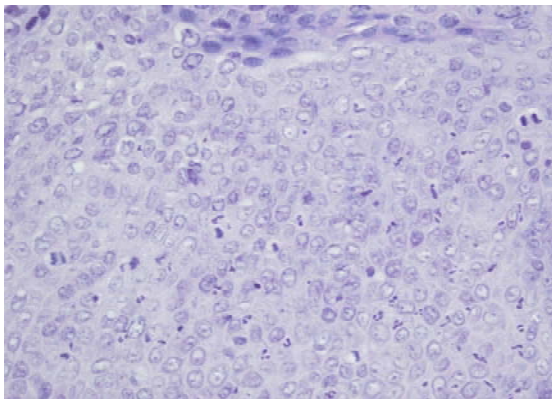


Figure 2

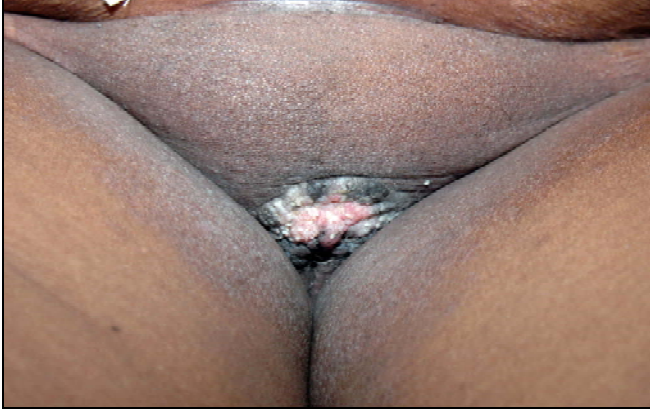

Figure 3

Q1. What is your diagnosis?