

## **Fulminant Amebic Colitis a Life Threatening Rare Entity**

Suhair Al-Saad, CABS, FRCSI\* Safa Abdulla Al Khwaja, CABM\*\* Sara Mathew George, MD, FRCPath\*\*\* Mariam Junaid, CABS\*\*\*\* Khadija Moheb, MBBS\*\*\*\*\*

**Objective:** To present two uncommon cases of Fulminant Amebic Colitis.

**Design:** Retrospective study.

**Setting:** Surgical and Medical Department at Salmaniya Medical Complex.

**Method:** From March to September 2008, two cases of fulminant Amebic Colitis were seen and reviewed as far as their presenting features, investigation, characteristic histopathologic picture, and management.

**Result:** Two cases of Amebic Colitis were found in the hospital records during the last ten years. Both presented to the clinic within the last six months. Both patients were males, young, from poor socio-economic class and are originally from Indian subcontinent. Both had vague and mild presentation. One progressed to massive lower GI bleeding and the other one progressed to colonic perforation and peritonitis. The second case had CT scan, which showed signs of colitis and suspected perforation but was not diagnostic of Amebic Colitis. The first case had subtotal colectomy and primary anastomosis; while, the second case had limited colectomy with proximal colostomy and distal mucus fistula. The diagnosis was based on histopathology of the resected specimens. Serology was confirmatory in only one patient.

**Conclusion:** Fulminant Amebic Colitis is a rare entity. Clinical awareness and early surgical intervention are very important in the outcome. Two cases of fulminant Amebic Colitis have been managed by colonic resection of the affected part, in addition to Metronidazole and broad-spectrum antibiotic.

*Bahrain Med Bull 2009; 31(1):*

Amebiasis is a worldwide disease, with significantly higher prevalence rates in developing countries because of poor socioeconomic conditions and sanitation levels.

---

\* Assistant Prof. Arabian Gulf University & Consultant Surgeon  
Dept of Surgery

\*\* Consultant Infectious Disease  
Dept of Medicine

\*\*\* Consultant Pathologist  
Dept of Pathology

\*\*\*\* Senior Resident in Surgery  
Dept of Surgery

\*\*\*\*\* Resident in Medicine  
Dept of Medicine  
Salmaniya Medical Complex  
Kingdom of Bahrain

The causative protozoan parasite, *Entamoeba Histolytica*, is a potent pathogen, secreting proteinases that dissolve host tissues, kill host cells on contact, and engulf red blood cells. It invades the intestinal mucosa, causing Amoebic Colitis. In some cases, amebas breach the mucosal barrier and travel through the portal circulation to the liver, where they cause abscesses<sup>1</sup>.

Ominous rare complication of intestinal amebiasis is fulminant colitis with extensive lower gastrointestinal bleeding or bowel necrosis leading to perforation and peritonitis. This tend to occur in approximately less than 1% of cases but it is associated with high mortality rate of more than 50%<sup>2</sup>.

The aim of this report is to present two cases of acute fulminating necrotizing Amebic Colitis to increase the awareness of the clinicians about their diagnosis and management.

## **CASE ONE**

Thirty-eight years old Nepali security guard, not known to have any previous medical illnesses, presented to the emergency with history of bilateral flank pain and vomiting of one day duration. The pain was associated with fever of two weeks duration. There was no history of loose motion or rectal bleeding.

Initial physical examination revealed hypotension of 80/60mmhg, while temperature was 36.7C and pulse was 100/minutes. Abdominal examination revealed vague fullness and tenderness in the lower abdomen. The rest of systemic examination was unremarkable. The investigations showed leukocytosis of  $18.2 \times 10^12/l$  and hemoglobin of 11.5g/dl. His urine analysis showed pyuria.

A diagnosis of urosepsis was made and the patient was admitted to the medical ward. Septic workup was done and IV antibiotic (Tazocin) was started. The result of septic workup was sterile.

Abdominal Ultra-sonography was done and showed right sided pleural effusion and mild ascites otherwise inconclusive.

During this time the patient continued to have unexplained hypotension not responding to IV rehydration. He was started on dopamine infusion and IV Metronidazole.

Within few days he developed sudden bloody diarrhea. Local rectal examination showed no fissures or piles.

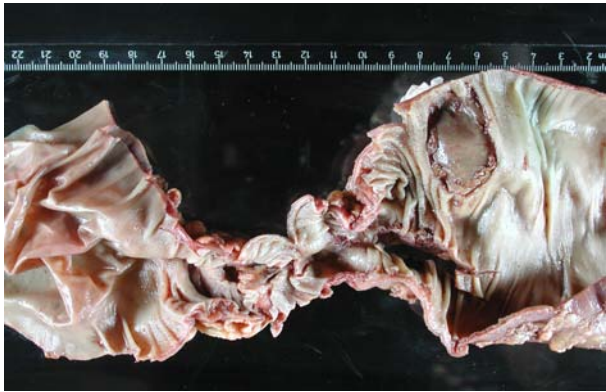Colonoscopy was done. The findings were multiple ulcers over the entire colon. Biopsies were taken and the bleeding ulcers were injected with adrenaline. The bleeding stopped temporarily and the result of histopathology was suggestive of non-specific colitis with ulcerations. During these days, he was transfused with 3 Units of Packed red blood cells.

Selective Angiography was done to define the site of bleeding but was inconclusive.

After one week, another massive fresh rectal bleeding occurred, his Hb dropped to 8 gm/dl and he collapsed. He was immediately transferred to the operating theatre, he was in hypovolemic shock.

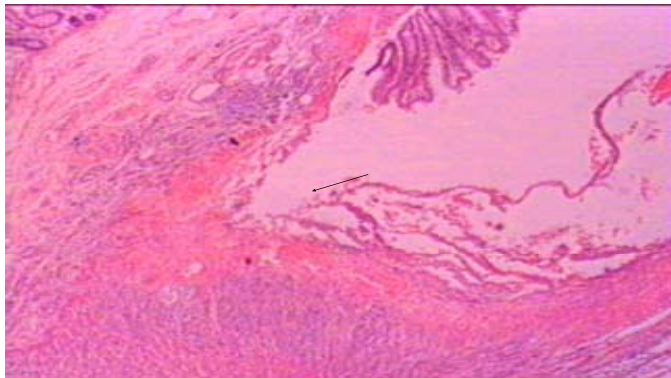
The patient was resuscitated, and transfused with packed red blood cells and fresh frozen plasma. In the operating theatre, colonoscopy showed multiple large and deep ulcers in the colon spreading to the sigmoid colon, some of which were massively bleeding. Laparotomy was performed and the involved part of the colon was resected (almost subtotal colectomy); this was followed by primary ileo-sigmoid anastomosis.

Postoperatively, the patient was managed in the ICU, where he recovered well. Histopathological result was suggestive of fulminant Amebic Colitis. Gross examination of the specimen showed a narrowed segment almost in the middle with dilated segments on either side (Toxic megacolon). The mucosa revealed multiple circular, deep ulcers, Figure 1.



**Figure 1 (case one): Gross Photograph Showing Megacolon with Thin Wall on the Left, Narrowed Central Part and Circular Ulcer on the Right**

On microscopy, these ulcers were deep, flask shaped, extending to the muscularis propria, Figure 2. Amebic trophozoites were not detected even after special stains. Serological test was positive for Amebiasis.



**Figure 2 (case one): Photomicrograph of Colon Showing Deep Flask Shaped Ulcer Extending to the Muscularis Propria (100x magnification)**

The patient continued on Metronidazole for a total of 2 weeks. Within one month the patient had full recovery and was discharged from the hospital. On follow-up visits the patient was well and asymptomatic.

## **CASE TWO**

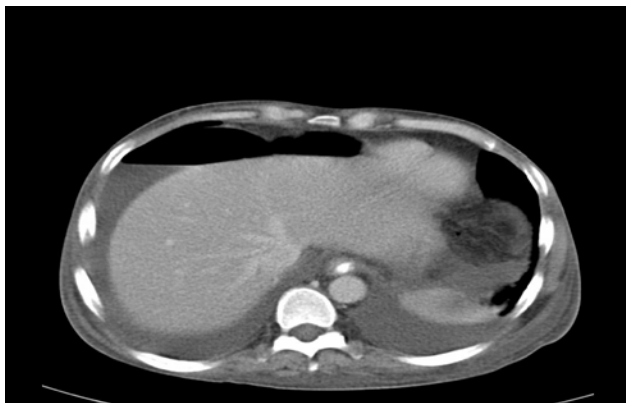
Thirty-four years old Bangladeshi male patient, working in Bahrain for the last 8 months, presented to emergency department with a history of malaise and fever of 5 days duration. He had past history of chronic abdominal pain with occasional vomiting, but no history of diarrhea.

On examination, the patient was pale, cachectic with ankle edema and ascites. The abdomen was tender with minimal guarding at the right upper quadrant. Laboratory investigations showed anemia with hemoglobin of 3.1 gm/dl (microcytic hypochromic anemia). Serum iron was very low. Liver function test showed hypoalbuminemia. Serum urea and creatinine were normal.

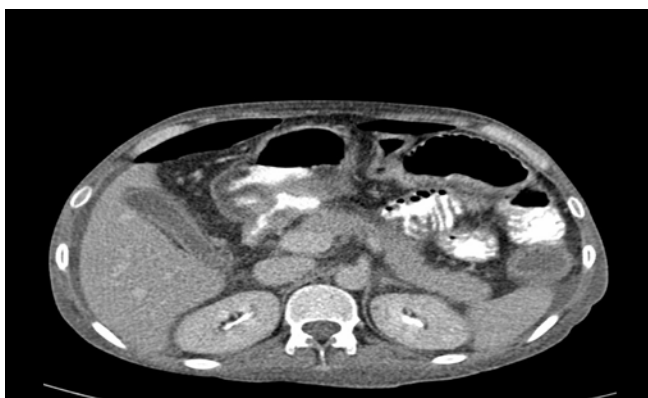Stool analysis was negative for occult blood and for Amebic cysts or trophozoites. *Strongyloides stercoralis* filariform larva was isolated in stool, for which Albendazole 400 mg twice daily was started.

During hospitalization he started to develop low grade fever and worsening of his abdominal pain and diarrhea. Abdominal examination showed vague tenderness all over, maximum at the epigastric region with minimal peritonism. His white cell count reached 24,000/cu.mm.

Chest radiographs revealed air under diaphragm. Abdominal CT-scan showed significant intra-peritoneal air and fluid collection, Figure 3. There was edema and transmural air in colonic wall, see Figure 4.



**Figure 3 (case two): Abdominal CT Scan Showing Significant Free Intra-peritoneal Air and Fluid Collection**



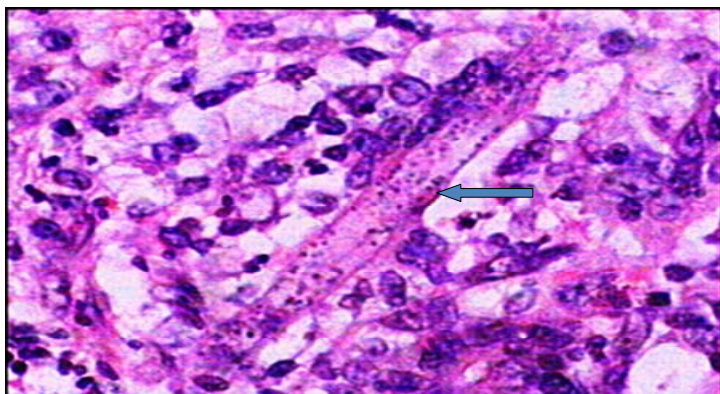
**Figure 4 (case two): Abdominal CT Scan Showing Significant Intra-peritoneal Air and Transmural Air and Edema of the Colonic Wall**

The patient was started on intravenous antibiotics (Tazocin 4.5 gm eight hourly and Metronidazole 500 mg eight hourly); he was given blood transfusion of 4 units and prepared for surgery.

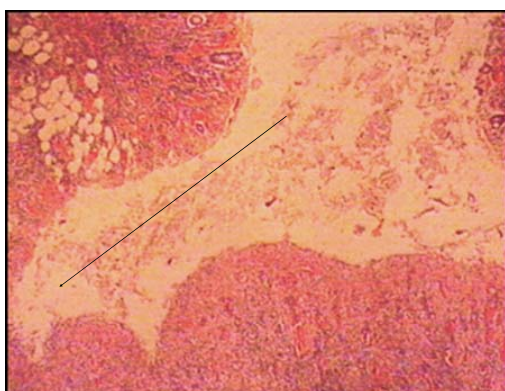
Laparotomy unveiled a single sealed perforation at the hepatic flexure and severely inflamed surrounding area of the colon. The perforation was 0.5 – 1 cm in size. There was minimal peritoneal contamination. The involved segment of the colon was resected with proximal colostomy and distal mucous fistula. Wide bore drains were left in the pelvis and the right paracolic gutter. Postoperatively, the patient was managed in the ICU.

He improved, the intra -abdominal drains were removed and the patient was discharged on the 6<sup>th</sup> day from the ICU.

Histopathologic examination of the resected colonic segment demonstrated dilated colon with multiple circular deep ulcers. Microscopy showed heavy infiltrate of lymphocytes, plasma cells, neutrophils and eosinophils in the mucosa, along with larva of strongyloides stercoralis (Figure 5). The ulcers were deep, flask shaped, extending to muscularis propria, some containing inflammatory exudates (Figure 6).



**Figure 5 (case two): Photomicrograph of Longitudinal Section of Strongyloides Stercoralis Larva (arrow) in the Colonic Mucosa Surrounded by Eosinophils (400x magnification)**



**Figure 6 (case two): Photomicrograph of Colon Showing Deep Flask Shaped Ulcer (arrow, 100x magnification)**

These features were compatible with Amebic Colitis and strongyloides stercoralis hyperinfection of the colon.

Strongyloides in its filariform larva was isolated from the stool but no amebic cyst or trophozoites were found.

Serology for Amebiasis was negative; while that for strongyloides was positive.

Based on clinical, laboratory and histopathologic findings, a diagnosis of amebiasis and strongyloides stercoralis co-infection was made.

The patient was treated with Albendazole for 10 days and Metronidazole for 16 days.

The patient was discharged without any postoperative complication. It was planned to close the colostomy after three months.

## **DISCUSSION**

Amebiasis is the second leading cause of death from parasitic disease worldwide. Infection with ameba occurs through ingestion of the cyst, then excystation occur in the large bowel. Cyst passed in the stool might remain viable for weeks and months in suitable environment, it may infect another person through fecal contamination of water and vegetables, which would explain why the disease have higher prevalence rates in areas with poor sanitation levels, such as India, Africa, Mexico and parts of Central and South America. In one study from Mexico, the seroprevalence of *E. Histolytica* was 8.4 %<sup>3</sup>. In another series from urban Bangladesh, children had 4.2% prevalence rate of *E. Histolytica* infection<sup>4</sup>. The two patients presented in this study were from Indian subcontinent.

In developed countries, amebiasis is mainly seen in immigrants from and travelers to endemic countries, institutionalized patients and sexually active homosexuals.

The strain of *E. Histolytica* as well as host factors such as genetic susceptibility, age and immunocompetence ultimately will determine whether infection leads to asymptomatic or invasive disease.

Ninety percent of *E. Histolytica* infection is asymptomatic, which usually spontaneously resolves within 12 months. Among those 10% with clinical amebiasis the onset is generally subacute for one to three weeks. Symptoms range from mild diarrhea to severe dysentery producing abdominal pain, diarrhea, and bloody stools (94 to 100%). Fever and weight loss are present in less than 40% of patients<sup>2,5</sup>.

Acute Fulminant Colitis is a rare complication of intestinal amebiasis and tend to occur in approximately less than one percent of cases but it is associated with high mortality rate of more than 50%<sup>2</sup>.

In comparison, chronic intestinal amebiasis can last for years and can mimic inflammatory bowel disease.

Ameboma, perianal cutaneous amebiasis, and rectovaginal fistulae are rare complications of amebic intestinal disease<sup>6-8</sup>.

Diagnosis of intestinal amebiasis depends mainly on histopathology and the presence of flask shaped ulcers in the mucosa.

In our cases the diagnosis was difficult to make from the clinical presentation or even colonoscopic or operative findings. It was only possible to reach the final diagnosis by histopathologic examination of the resected specimens and was confirmed the serology.

Stool microscopy is a relatively poor method because it has low sensitivity (30%)<sup>5</sup>. In our cases stool examination was negative for ameba. Antigen detection assays of the stool are one of the best current means, they are sensitive, specific, rapid, easy to perform; but the test is not currently available in all clinical laboratory<sup>5</sup>.

Serology with antibody measurements is widely available, with high sensitivity of 85% in Amebic Colitis and 95% of amebic liver abscess, but the problem is that it may remain positive for years; which might give false positive result, especially in endemic area<sup>9</sup>. Serology was positive in our first patient but was negative in the second. It has been reported previously that 15% of invasive Amebic Colitis would have negative ameba serology<sup>9</sup>.

Visual inspection of the colon by sigmoidoscopy and/or colonoscopy can be performed to reach the diagnosis. Scrapings or biopsy specimens, may be positive for cysts or trophozoites on microscopy if the treatment was not initiated, usually Metronidazole is started empirically. Colonic lesions in amebic dysentery range from non-specific mucosal thickening and inflammation to classic flask-shaped amebic ulcers<sup>9</sup>.

In most of the previously reported cases who presented with fulminant colitis mandating urgent surgical intervention, the correct diagnosis was only established after reviewing the surgical specimen or biopsies obtained intra-operatively as in the two presented patients. In few cases the diagnosis was suspected based on the intra-operative morphological appearance of the colon<sup>10-12</sup>.

E. Histolytica infection should always be treated even in asymptomatic individuals because of the potential risk of developing invasive disease and the risk of spread to family members. Metronidazole is the agent of choice for intestinal amebiasis, with a cure rate of approximately 90%<sup>13,14</sup>.

Intensive anti-amebic therapy should be instituted as soon as possible; otherwise surgical therapy is likely to fail.

In patients who have suspected or proven peritonitis, broad spectrum antibacterial therapy should also be added to Metronidazole.

Surgical intervention is often required for acute fulminant Amebic Colitis complicated by toxic megacolon or colon perforation<sup>15,16</sup>.

A staged operation is highly recommended for complicated fulminant Amebic Colitis particularly if there was peritoneal contamination as it did happen in the second case.

The first stage should be aggressive resection of the involved colon with exteriorization of the proximal and distal transected ends, i.e. an ileostomy and mucus fistula. Further bowel reconstruction should be deferred 3-6 months<sup>17</sup>.

The two cases in this report had fulminant Amebic Colitis. The initial admitting diagnosis was unrelated and unexpected. The first patient had toxic megacolon and extensive lower gastrointestinal bleeding and the second patient had perforation. Such a complication of acute necrotizing colitis secondary to amebic infection have been reported previously in many case reports and case series<sup>18,19</sup>. It tend to occur usually among patients with certain risk factor such as young age, pregnancy, corticosteroid treatment, malignancy, malnutrition, or alcoholism. The first patient did not have any risk factor to develop such a complication, while the second patient had chronic malnutrition with severe iron deficiency anemia and hypoalbuminemia possibly secondary to malabsorption with protein losing enteropathy caused by parasitic infestation with strongyloidiasis; this has been described previously in the literature that high intestinal worm burden with strongyloides has been strongly associated with chronic enterocolitis and malabsorption<sup>20</sup>.

## CONCLUSION

**Fulminant Amebic Colitis is a rare entity, it is less than 1%. It should be considered as one of the differential diagnosis among patients who present with severe colitis or massive lower G.I. bleeding particularly those who are originally from endemic area such as India, Bangladesh, and part of Africa. The diagnosis depends mainly on histopathology of the biopsies, or the surgical specimen.**

**The management is a combination of both surgical resection and intravenous Metronidazole. A broad spectrum antibiotic is needed to cover the super added infection. Early surgical intervention is very important for a favorable outcome.**

## REFERENCES

1. Haque R, Faruque ASG, Hahn P, et al. Entamoeba Histolytica and Entamoeba Dispar Infection in Children in Bangladesh. *J Infect Dis* 1997; 175: 734-6.
2. Aristizabal H, Acevedo J, Botero M. Fulminant Amebic Colitis. *World J Surg* 1991; 15: 216-21.
3. Weinke T, Friedrich-Jänicke B, Hopp P, et al. Prevalence and Clinical Importance of Entamoeba Histolytica in Two High-Risk Groups: Travelers Returning from the Tropics and Male Homosexuals. *J Infect Dis* 1990; 161: 1029-31.
4. Stanley SL Jr. Amoebiasis. *Lancet* 2003; 361: 1025-34.
5. Petri WA Jr. Recent Advances in Amebiasis. *Crit Rev Clin Lab Sci* 1996; 33: 1-37.
6. Stockinger ZT. Colonic Ameboma: It's Appearance on CT: Report of a Case. *Dis Colon Rectum* 2004; 47: 527-29.
7. Misra SP, Misra V, Dwivedi M. Ileocecal Masses in Patients with Amebic Liver Abscess: Etiology and Management. *World J Gastroenterol* 2006; 12: 1933-6.
8. Kenner BM, Rosen T. Cutaneous Amebicasis in a Child and Review of the Literature. *Pediatr Dermatol* 2006; 23: 231-4.
9. Patterson M, Healy GR, Shabot JM. Serologic Testing for Amebiasis. *Gastroenterology* 1980; 78(1): 136-41.
10. Haque R, Petri WA Jr. Diagnosis of Amebiasis in Bangladesh. *Arch Med Res* 2006; 37(2): 273-6.
11. Mendonca HL Jr, Vieta JO, Korelitz BI. Perforation of the Colon in Unsuspected Amebic Colitis: Report of Two Cases. *Dis Colon Rectum* 1977; 20(2): 149-53.
12. Abbas MA, Mulligan DC, Ramzan NN, et al. Colonic Perforation in Unsuspected Amebic Colitis. *Dig Dis Sci* 2000; 45(9): 1836-41.



13. Li E, Stanley SL. Amebiasis. *Gastroenterol Clin North Am* 1996; 25: 471-92.
14. Haque R, Huston CD, Hughes M, et al. Amebiasis. *N Engl J Med* 2003; 348: 1565-73.
15. Ishida H, Inokuma S. Fulminant Amebic Colitis with Perforation Successfully Treated by Staged Surgery: A Case Report. *Journal of Gastroenterology* 2003; 38: 92-6.
16. Hsu YB, Chen FM, Lee PH, et al. Fulminant Amebiasis: A Clinical Evaluation. *Hepatogastroenterology* 1995; 42(2): 109-12.
17. Hwa-zong Chen, Yung-Hsiang Hsu<sup>1</sup>, Yao-Zen Chang. Fulminant Amebic Colitis: Recommended Treatment to Improve Survival. *Tzu Chi Med J* 2004; 16: 1-8.
18. Hasan M, Islam MA, Siddiqua SS, et al. Colonic Perforation Due to Necrotizing Amoebic Colitis *Mymensingh Med J* 2003; 12(1): 61-3.
19. Wig JD, Kaushik SP, Saleem MA, et al. Amebic Perforation of the colon. *Am Surg* 1975; 41(7): 429-31.
20. Scowden EB, Schaffner W, Stone WJ. Overwhelming Strongyloidiasis: An Unappreciated Opportunistic Infection. *Medicine* 1978; 57: 527-44.