

Keratoacanthoma: An Unusual Presentation

Ibrahim A Al-Hoqail, M.D* Taseer A Bhatt, M.D**

Keratoacanthoma is an epithelial neoplasm occurring on the sun exposed skin of elderly persons. It usually presents as solitary flesh colored nodule with central keratin plug and is characterized by rapid growth followed by spontaneous regression in weeks to months. We present a 45 year old male with keratoacanthoma on forehead present for a long time with recent rapid increase in growth following trauma.

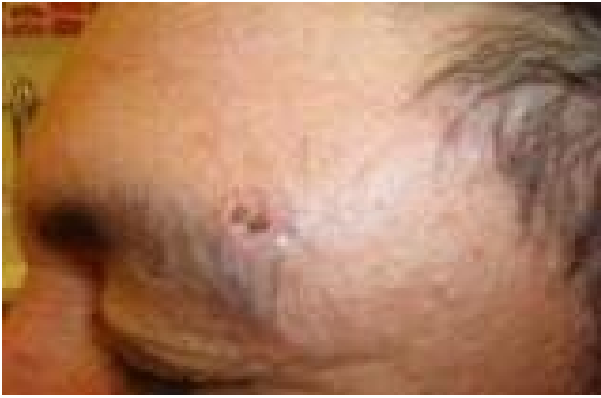Bahrain Med Bull 2009; 31(1):

Keratoacanthoma is an exophytic epithelial growth which appears clinically as sharply demarcated keratotic nodule, it is characterized by rapid growth and spontaneous regression with residual scarring. It is considered benign growth but evidence is accumulating in favor of a low grade squamous cell carcinoma¹. There are various types of keratoacanthomas which include the solitary and the multiple forms of keratoacanthoma. The solitary forms of keratoacanthoma are most commonly seen in middle aged individual on the sun exposed areas of hair bearing skin. However the entire evolution of the lesion usually span from weeks to months. The persistence of keratoacanthoma for a very long time followed by a late spurt in growth has not been reported previously in literature.

CASE REPORT

A forty-five years old male presented to the Dermatology clinic of King Fahad Medical City, Riyadh with nodular growth on the forehead near the left eyebrow of 20 years duration. The growth had shown a recent rapid increase in growth following a blunt trauma to the lesion about a year ago. On examination, the growth was skin colored and the margins were well demarcated, figure 1.

On the initial assessment of the patient, we did not take pre-biopsy photographs of the lesion as we were concerned for patient's condition. However, we took the photographs only after seeing the histopathology assessment because it was a unique presentation.



**Figure 1: Post Biopsy Photograph of the Keratoacanthoma on the Forehead
61.214 x 79.756mm (300x300 DPI)**

-
- * Founding Dean, Consultant and Associate Professor in Dermatology
Faculty of Medicine
 - **Assistant Consultant of Dermatology
Internal Medicine Department
King Fahad Medical City
Riyadh, Saudi Arabia

The center of the nodule showed a crater like depression filled with brownish thick material. The nodule was non-tender and firm without any infiltration of the surrounding skin. There was no evidence of dermatoheliosis.

Histologically, the lesion demonstrates a cup shaped invagination of squamous epithelium with abundant cytoplasm surrounding a central crater of parakeratotic and hyperkeratotic material. The lesion extends deep into the dermis, figure 2.

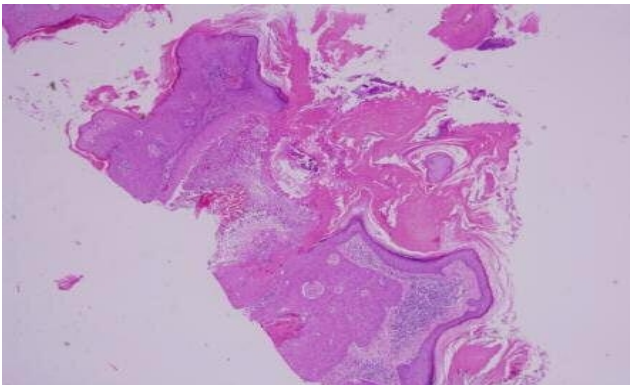


Figure 2: Cup Shaped Invagination of Squamous Epithelium Surrounding a Central Crater of Parakeratotic and Hyperkeratotic Material 63.246 x 83.82mm (300 x 300 DPI)

DISCUSSION

The term keratoacanthoma was coined by Freudenthal in 1940 in view of considerable acanthosis seen on the histopathological examination. Keratoacanthoma is common neoplasm seen mainly on the photo exposed portions of body as solitary growth with central keratin filled plug. The tumor is characterized by rapid growth in the proliferative stage followed by spontaneous regression. It is regarded as an immunologically well controlled low grade squamous cell carcinoma. The aggressive transformation to neural and vascular invasion and metastases to regional lymph nodes is frequently seen in older patients and the immunocompromised^{3,4}. The rare variants of keratoacanthomas are seen in both solitary and multiple forms of keratoacanthoma. Keratoacanthoma of solitary form includes the subungual, mucosal, giant and keratoacanthoma centrifugum marginatum; the multiple type of keratoacanthoma includes multiple self healing keratoacanthoma of Ferguson smith, multiple eruptive Keratoacanthoma of Grzybowski type. Multiple keratoacanthoma are seen in an autosomal dominant genodermatosis Muir-Torre syndrome and in familial keratoacanthoma of Witten and Zak⁵⁻¹⁰. The solitary keratoacanthoma begins as a macule and shows rapid growth in the proliferative stage, may reach a size of 30 mm in 6-8 weeks; in the next stage it maintains the crater form shape filled with keratin plug and finally it is followed by spontaneous resolution with expulsion of keratin plug leaving a atrophic hypopigmented scar. The entire process from origin to spontaneous resolution usually takes about 4-9 months¹¹.

The etiology of the lesion is uncertain, but UV light, viruses, chemical carcinogens, and immunosuppressive drugs have been suggested as contributory factors¹². Keratoacanthoma of oral cavity and lips in the Middle East is known to occur in smokers of “Shisha” and “Goza” which contains a mixture of crude tobacco fermented with molasses and fruits¹³.

CONCLUSION

The solitary keratoacanthoma on the forehead of this patient was unusual due to a persistence of this tumor for almost two decades and followed by a late proliferative growth phase. This unique presentation has not been reported previously in literature.

REFERENCES

1. Patel A, Halliday GM, Cooke BE, et al. Evidence that Regression in Keratoacanthoma is Immunologically Mediated: a Comparison with Squamous Cellcarcinoma. Br J Dermatol 1994; 131: 789-98.
2. Barnetson RS, Halliday GM. Regression in Skin Tumours: A Common Phenomenon. Australas J Dermatol 1997; 38: 63-5.
3. Gottfarstein-Maruani A, Michenet P, Kerdraon R. Keratoacanthoma: Two Cases with Intravascular Spread. Ann Pathol 2003; 23: 438-42.
4. Hodak E, Jones RE, Ackerman AB. Solitary Keratoacanthoma is a Squamous Cell Carcinoma: Three Examples with Metastases. Am J Dermatopathol 1993; 15: 332-42.
5. Sinha A, Marsh R, Langtry J. Spontaneous Regression of Subungual Keratoacanthoma with Reossification of Underlying Distal Lytic Phalynx. Clin Exp Dermatol 2005; 30: 20-2.

6. Janette A, Pecaro B, Lonergan M. Solitary Intraoral Keratoacanthoma: Report of a case. *J Oral Maxillofac Surg* 1996; 54: 1026-30.
7. Hofer SO, Jackson IT. Self-involution of Giant Keratoacanthoma on the Tip of the Nose. *Plast Reconstr Surg* 2004; 113: 765-6.
8. Ferguson-Smith J. Multiple Primary, Self-healing Squamous Epithelioma of the Skin. *Br J Dermatol* 1948; 60: 315-8.
9. Ponti G, Losi L, Di Gregorio C. Identification of Muir–Torre Syndrome among Patients with Sebaceous Tumors and Keratoacanthomas: Role of Clinical Features, Microsatellite Instability, and Immunohistochemistry. *Cancer* 2005; 103: 1018-25.
10. Agarwal M, Chander R, Karmakar S. Multiple Familial Keratoacanthoma of Witten and Zak – A Report of Three Siblings. *Dermatology* 1999; 198: 396-9.
11. Griffiths RW. Keratoacanthoma Observed. *Br J Plast Surg* 2004; 57: 485-501.
12. Wynder EL, Bross IJ, Feldman RM. A Study of the Etiological Factors in Cancer of the Mouth. *Cancer* 1957; 10:1300-23.
13. Ibrahim E, El-Hakim, Mirghani A.E. Uthman. Squamous Cell Carcinoma and Keratoacanthoma of the Lower Lip Associated with "Goza" and "Shisha" Smoking. *International Journal of Dermatology* 1999; 38: 108-10.