

## **Rib Exostosis: An Incidental Finding**

Mona MKA Youssef Booz, FFR-RCSI\* GR Nair, MS, MCh, FIACS\*\*

**We report an 18 year old young man with bronchial asthma presenting with productive cough for one month. His chest radiograph and computed tomography (CT) demonstrated an exostosis of the right first rib, which was an incidental finding not related to his complaint. We report the radiological findings and complications that may accompany rib exostosis.**

*Bahrain Med Bull 2009; 31(1):*

Osteochondromas (exostosis) are the most common neoplasm of bone and arise from the metaphysis of bones. The tumors typically begin to grow before puberty and continue until bone maturation is reached. Surgery is required in childhood if these lesions are painful or disfiguring, while those arising in adulthood should always be resected. Tumors of the chest wall represent 2% of all tumors of the body, they may be primary or metastatic, benign or malignant<sup>1</sup>. Approximately 60% of the resected tumors are primary<sup>1</sup>. Only 10% of rib tumors are benign, and osteochondromas, the most common benign bone tumor, account for half of these<sup>2</sup>. Exostosis of inner aspect of ribs may damage the adjacent structure; therefore, it is advised to be resected.

### **CASE REPORT**

An 18 year old young man who is a known asthmatic since the age of four, presented with exacerbation of asthma, he had productive cough on and off for one month with no fever.

On examination he had sporadic wheezes and basal crepitations. His white cell count (WBC) was  $5.7 \times 10^9/l$ , Polymorphs 36%, Lymphocytes 50%, Monocytes 9%, Eosinophils 4% and Basophils 1%.

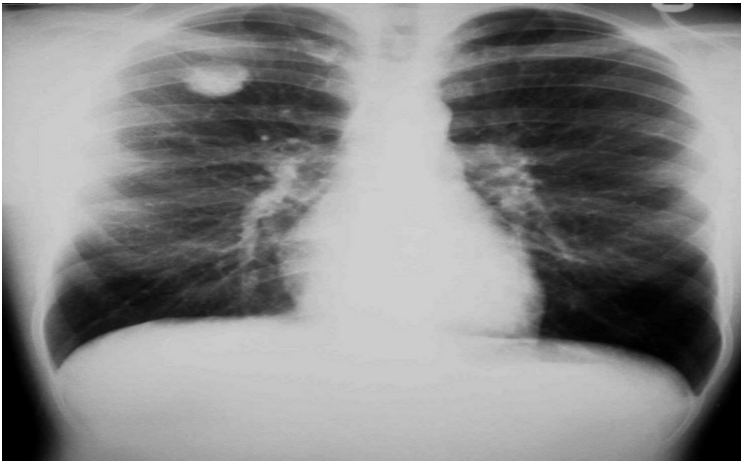Chest x-ray showed 3x3 cm rounded patchy heterogeneous dense opacity in the right lung apex in figure 1, it is anterior and abutting posterior wall of sternum as seen in lateral chest x-ray in figure 2. The adjacent lung looked normal. Ribs showed no expansion, erosions or destruction. No hilar, mediastinal masses or pleural effusion were detected. Lungs were hyperinflated. A granuloma was suspected.

Sputum analysis showed acute on chronic inflammatory changes. No fungal or mycobacterial organisms were detected.

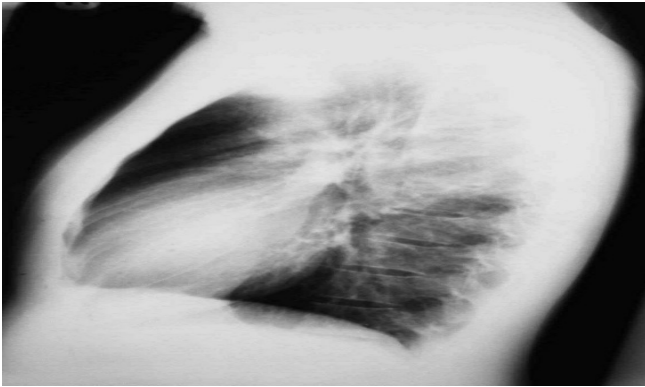
---

\* Consultant Radiologist  
Department of Radiology

\*\* Consultant Cardio-Thoracic and Vascular Surgeon  
Department of Cardiology  
Salmaniya Medical Complex  
Kingdom of Bahrain



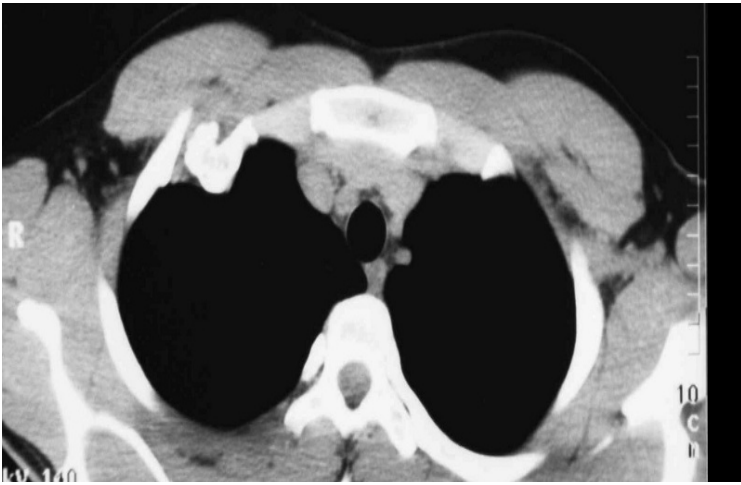**Figure 1: A Posteroanterior (PA) Chest X-Ray Showing a Rounded Patchy Heterogeneous Dense Opacity 3x3 cm in Right Apex**



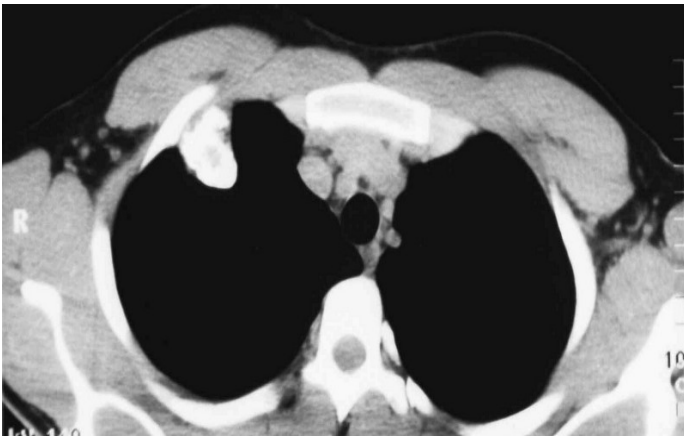**Figure 2: A Lateral Chest X-Ray Showing the Lesion Anteriorly and Abutting the Posterior Wall of the Sternum**

Clinically the patient improved after receiving a course of antibiotics and increasing the frequency of steroid inhalation that he was using since the age of five years.

Since the right apical lesion persisted, chest CT was performed which revealed a sessile exostosis 4x3 cm arising from inner wall of right first rib's costochondral junction extending beneath the second rib, pushing the pleura and lung apex inwards (figure 3a and b). No other exostoses were found.



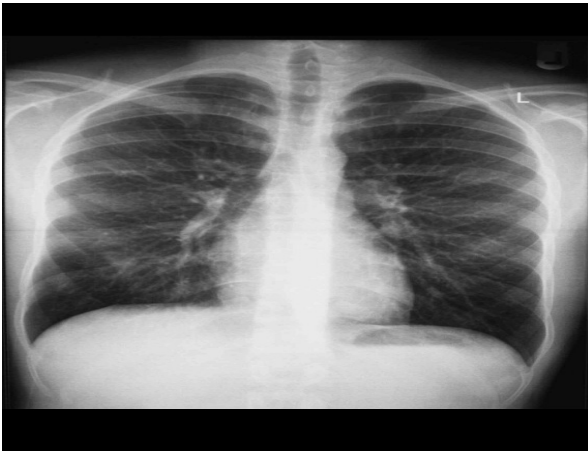**Figure 3 (a)**



**Figure 3 (b)**

**Figure 3 (a and b): CT Scan of the Chest Demonstrating a Sessile Exostosis 4x3 cm Arising from Right First Rib's Costochondral Junction Extending beneath the Second Rib, Pushing the Pleura and the Lung Inwards**

Surgical treatment was recommended. A short right anterior thoracotomy was performed and resection of the exostosis with part of the first rib and overlying pleura. Underlying lung looked healthy, so the wound was closed without an intercostal drainage tube. The patient had an uneventful recovery; he was discharged on the third postoperative day. Histopathology confirmed the lesion as an osteochondroma. He remains well at follow-up one year later; he is still asthmatic and using steroid inhalers (figure 4).



**Figure 4: Postoperative Chest X-Ray with No Evidence of the Exostosis and Normal Lung Parenchyma**

## **DISCUSSION**

Tumors of the chest wall comprise approximately 2% of all tumours of the body and may be primary or metastatic, benign or malignant. Approximately 60% of the resected tumours are primary<sup>1</sup>.

Sixty per cent of primary tumours are malignant and mostly are of bony origin. Only 10% of rib tumours are benign, and osteochondromas, the most common benign bone tumour, account for half of these<sup>2</sup>.

The tumor occurs more frequently in men, with a male/female ratio of 3:1. Osteochondromas begin in childhood and grow until completion of skeletal maturity. They develop from an aberrant focus of growth-plate cartilage beneath the Ring of Ranvier, which continues to grow and undergo enchondral ossification in parallel with general skeletal growth<sup>3</sup>. When skeletal maturity is reached, the cartilage cap thins and eventually completely ossifies.

Osteochondromas are frequently asymptomatic and the development of pain may signify malignant degeneration.

Osteochondromas have a characteristic radiographic appearance, a sessile or stalked exostosis whose pedicle merges with the adjacent cortex, a peripheral rim of calcification and stippled calcification within the tumour mass. It may reach 10 to 15 cm in size, but most of them measure less than 5 cm.

Ninety per cent are solitary but can occur in multiple sites. The complications of solitary osteochondroma are often the result of mechanical interference with neighboring anatomic structures<sup>4</sup>. As the lungs move during respiration, the exostosis can injure the lung-giving rise to pneumothorax, or haemothorax by rubbing the diaphragm, pleura or heart<sup>4, 5, 6, 7, 8</sup>.

Osteochondroma may cause compression of adjacent vascular or neural structures<sup>9</sup>. Secondary chondrosarcoma is an exceedingly rare occurrence. Reports illustrate that rib

exostosis can present acutely as a life-threatening bleeding or as chronic complication in the form of pneumonitis and empyema<sup>10</sup>. Therefore, surgical treatment was recommended in the case presented.

The exostosis found in our patient was an incidental finding, detected when he had a chest radiograph. He had exacerbation of asthma for one month, which was attributed to repeated dust storms.

The appearance of the chest radiograph raised the possibility of a granuloma of fungal nature, but CT chest showed a sessile exostosis arising from the right first rib, extending beneath the second rib, displacing the pleura and lung inwards.

## CONCLUSION

**A case of exostosis arising from the costochondral junction of right first rib was excised surgically. Histopathology confirmed the lesion to be osteochondroma.**

## REFERENCES

1. Cemil M, Purut MD. Lesions of the Chest Wall. In: Sabiston DC, Lyster HK, ed. Text Book of Surgery, the Biological Basis of Modern Surgical Practice. 15<sup>th</sup> ed. Philadelphia, USA: WB Saunders, 1997; 1896-97.
2. Pairolero PC. Chest Wall Tumours. In: Shields TW, ed. General Thoracic Surgery, 4<sup>th</sup> ed. Malvern, PA, Williams & Wilkins, 1994; 579.
3. D'Ambrosia R, Ferguson A. The Formation of Osteochondroma by Epiphyseal Cartilage Transplantation. Clin Orthop 1968; 61: 103-15.
4. Uchida K, Kurihara Y, Sekiguchi S, et al. Spontaneous Haemothorax Caused by Costal Exostosis. Eur Respir J 1997; 10: 735-6.
5. Harrison NK, Wilkinson J, O'Donohue J, et al. Osteochondroma of the Rib: An Unusual Cause of Haemothorax. Thorax 1994; 49: 618-9.
6. Teijeira FJ, Baril C, Younge D. Spontaneous Haemothorax in A Patient with Hereditary Multiple Exostoses. Ann Thorac Surg 1989; 48: 717-8.
7. Buchan KG, Zamvar V, Mandana KM, et al. Juxtacardiac Costal Osteochondroma Presenting as Recurrent Haemothorax. Eur J Cardiothorac Surg 2001; 20: 208-10.
8. Balastskii AV, Ruisnouwich UE, Reshetrikova UK. Case of Traumatic Haemothorax in a Child with Multiple Cartilaginous Exostoses. Pediatriia 1973; 52: 82-4.
9. Anastasi GW, Werthemer HM, Brown JR. Popliteal Aneurysm with Osteochondroma of the Femur. Arch Surg 1963; 87: 636-9.
10. Hajjar WM, El-Medany YM, Essa MA, et al. Unusual Presentation of Rib Exostosis. Ann Thorac Surg 2003; 75: 575-7.