

## **The Role of Performing Prone Stress in Myocardial Perfusion Scintigraphy**

Hussain Meer, MD\* Naima Al Bulushi, MD\* Abd Aziz Al Sugair, MD\*\*  
Mohi Abozaid, MD\*\* Ayman Al Riffai, MD\*\*

**Background:** One of the major limitations of myocardial scintigraphy is soft tissue attenuation, which could be interpreted as a true perfusion defects, particularly diaphragmatic and bowel attenuation of the inferior wall.

**Objective:** The aim of this study was to evaluate the role of adding prone scan to the stress myocardial scintigraphy.

**Setting:** Department of Radiology, Nuclear Medicine Section, King Faisal Specialist Hospital and Research Center.

**Design:** Retrospective study.

**Method:** Eighty-eight patients with coronary artery disease had myocardial perfusion scan and were reported with and without a prone scan during stress study. All patients in this study had a diagnostic coronary angiogram.

**Patients who had coronary angiogram within one month after the diagnostic cardiac scan were included. Patients who have been admitted to the hospital between the two procedures were excluded.**

**Result:** Prone scan had improved the sensitivity (SN), specificity (SP), positive and negative predictive value (PPV, NPV) of the myocardial perfusion scintigraphy studies. Prone scan showed that SN, SP, PPV and NPV were, 91.7%, 70%, 78.6% and 87.5% compared to supine scan, which were 76.6%, 53.6%, 65.4% and 66.7%.

**Conclusion:** In this study, we have found that the sensitivity and specificity had improved after the addition of prone stress scan in myocardial perfusion studies.

**Prone scan had helped in differentiating perfusion defects from attenuation artifacts, leading to improvement of detecting the true perfusion defects.**

*Bahrain Med Bull 2011; 33(1):*

---

\* Fellow

\*\*Consultant

Department of Radiology

Nuclear Medicine Section

King Faisal Specialist Hospital & Research Center

Riyadh-Kingdom of Saudi Arabia

Email: hussainmeer@hotmail.com

Myocardial perfusion scan is a common study performed in nuclear medicine and a vital procedure for the evaluation of reversible cardiac wall ischemic defects in high risk patients<sup>1-2</sup>.

It consists of two parts; rest study which is done by injecting the radiotracer and to scan the patient while at rest, and stress part in which the patient is stressed either pharmacologically or by performing physical exercise to increase the heart rate above a particular rate, then the radiotracer is injected and the scan is performed<sup>2-3</sup>.

Both scans are performed while the patient is supine. Many centers are adding a third scan which is in prone position in stress study in order to reduce the attenuation artifact mainly for the inferior wall of the left ventricle<sup>4-7</sup>.

Some studies did not find any significant difference after adding prone scan to the examination<sup>13</sup>. In addition to that, prone scan might cause false-positive anteroseptal and anterior wall defects and it is not recommended to use prone scan without supine imaging. Coronary angiogram is, however, the golden standard method for evaluating the presence or absence of significant coronary artery stenosis<sup>8</sup>.

Several artifacts may obscure mainly the inferior wall; it can be avoided by scanning the patient in prone position<sup>4,6,7</sup>. Some centers are using SPECT-CT technology to avoid these artifacts by using CT scan for the attenuation correction mainly for the inferior wall<sup>9</sup>. However, keep in mind that the patient would receive more radiation<sup>10-12</sup>. In addition to that, SPECT-CT is not available everywhere. However, the combination of prone and supine techniques requires more time for scanning and a small proportion of patients can not lie in the prone position.

Several studies reported false positive scan of the inferior wall due to diaphragmatic attenuation and other artifact<sup>13-17</sup>.

The aim of this study was to evaluate the role of adding prone scan to the stress myocardial scintigraphy.

## **METHOD**

Cardiac perfusion performed from December 2005 till March 2007 was included. Patients who had coronary angiogram within one month after the diagnostic cardiac scan were included. Patients who have been admitted to the hospital between the two procedures were excluded.

Patients were reviewed independently by three radiologists specialized in nuclear medicine; only findings that have been agreed by two or more were approved. Each case was reported twice; one using stress prone technique and the other without.

A 5-point scoring system was used by the readers (0 = normal, 1 = equivocal, 2 = moderate reduction of isotope uptake, 3 = sever reduction of uptake, 4 = absent perfusion in the segment). The readers were asked to rank the findings as normal, probably normal, equivocal, probably abnormal or abnormal<sup>18</sup>.

Comparison with diagnostic angiogram was made in order to calculate the sensitivity and specificity of every protocol.

Abnormal perfusion was defined as involving two segments of the 20 segmental model of the left ventricle approved by two readers. Stenosis in angiogram was defined as 70% of the feeding artery.

Patients had been scanned using single day protocol giving 370MBq for the rest study and followed by stress examination using 1110MBq. The radiotracer used was technetium 99m labeled Sestamibi (Cardiolite).

Stress examination was done in supine and prone positions<sup>19-21</sup>.

## RESULT

One thousand and ninety-six patients were reviewed; only 89 (8.1%) had a diagnostic coronary angiogram within a month period from the perfusion study. One patient was excluded because of admission due to chest pain. Therefore 88 were the subjects of the study, 61 were males and 27 were females (69.3% and 31% respectively). The mean age was 59.4 years and the age ranged between 36 to 77 years. Forty-seven patients had pharmacological stress examination and 41 had exercise stress. Table 1 shows the comparison between cardiac scan and coronary angiogram.

**Table 1: Comparison between Cardiac Scan and Coronary Angiogram**

	True +ve	True -ve	False +ve	False -ve	Total
With prone	44	28	12	4	88
Without prone	36	22	19	11	88

True +ve: perfusion defect compatible with coronary artery stenosis more than 70%

True -ve: normal scan with normal angiogram

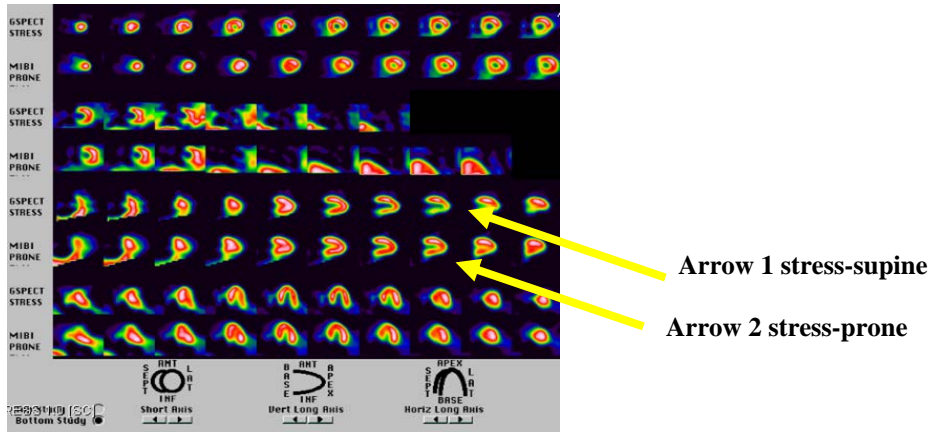
False +ve: perfusion defect with normal angiogram

False -ve: normal perfusion with coronary artery stenosis more than 70%

Table 2 shows the calculated sensitivity, specificity, positive and negative predictive values. Figure 1 shows the artefact attenuation correction in prone position in the inferior wall of the left ventricle compared to supine position.

**Table 2: Calculated Sensitivity, Specificity, Positive and Negative Predictive Values**

	With prone	Without prone
Sensitivity	91.7%	76.6%
Specificity	70%	53.6%
Positive predicted value	78.6%	65.4%
Negative predicted value	87.5%	66.7%



**Figure 1: Homogenous Attenuation in the Inferior Wall in Stress Examination (Arrow 1) and Normal Perfusion for the Same Region on Prone Scan (Arrow 2)**

In this study, prone stress scan had improved our diagnoses in 41 patients (46.6%). In 20 (22.7%) patients, it was considered significant (more than two segments). The prone scan of three patients (3.4%) gave false information (not approved by the angiogram).

## DISCUSSION

In this study, we found that the addition of prone stress scan provided some additional information in 41 (46%) patients. In 20 (22.7%) patients, the additional information was considered significant (more than two segments). In 3 (3.4%) patients, the prone images added false information (not proved by the angiogram). The false information could be due to other artifact such as motion artifact.

Other studies found that the quality of the reports has been improved by adding prone scan to the protocol<sup>13</sup>. In order to minimize the false positive results in myocardial perfusion scan, it is important to avoid attenuation artifact. The left hemidiaphragm may cause attenuation over the inferior wall due to their anatomical location. However, prone position will keep the diaphragm away and consequently the attenuation will be eliminated<sup>14</sup>. In this study, changes of the images findings have been noticed in 46% of the cases after the addition of prone scan images.

In this study, we noticed a significant increased of the sensitivity of detecting the abnormality from 76.6% to more than 90% due to the increase of the true positive findings and reduction of the false negative. Eight patients (9.1%) out of 88 showed true findings where supine scans were wrongly negative and 7 (7.9%) were wrongly reported positive in supine became true negative. The specificity had increased from 53.6% to 70% after addition of prone in the protocol. The specificity was low in general in this sample due to false positive findings caused by motion or breast attenuation in obese patients or women with big breasts.

The unique issue about this study is that we are comparing the study group with itself where prone study has been added for the same patients who had rest and stress scan in supine. In addition, the result has been compared to coronary angiography for the sample group within one month only.

## CONCLUSION

**In this study, we have found that the sensitivity and specificity had improved after the addition of prone stress scan in myocardial perfusion studies.**

**We strongly recommend stress prone technique in myocardial perfusion examinations, especially in the absence of SPECT-CT technology, to improve the sensitivity and specificity without extra radiation to the patients.**

**Stress prone scan addition significantly enhances the sensitivity and specificity of myocardial perfusion examinations as revealed in this study.**

Submission date: 18.08.2010. Acceptance date:28.12.2010

## REFERENCES

1. DePuey EG. How to Detect and Avoid Myocardial Perfusion SPECT Artifacts. *J Nucl Med* 1994; 35(4): 699-702.
2. Slomka PJ, Nishina H, Abidov A, et al. Combined Quantitative Supine-prone Myocardial Perfusion SPECT Improves Detection of Coronary Artery Disease and Normalcy in Women. *J Nucl Cardiol* 2007; 14(1): 44-52.
3. Segall GM, Davis MJ. Prone Versus Supine Thallium Myocardial SPECT: A Method to Decrease Artifactual Inferior Wall Defects. *J Nucl Med* 1989; 30(4): 548-55.
4. Kiat H, Van Train KF, Friedman JD, et al. Quantitative Stress-redistribution Thallium-201 SPECT Using Prone Imaging: Methodologic Development and Validation. *J Nucl Med* 1992; 33: 1509-15.
5. Takahashi Y, Murase K, Higashino H, et al. Attenuation Correction of Myocardial SPECT Images with x-ray CT: Effects of Registration Errors between X-ray CT and SPECT. *Ann Nucl Med* 2002; 16(6): 431-5.
6. Hunold P, Vogt FM, Schmermund A, et al. Radiation Exposure during Cardiac CT: Effective Doses at Multi-detector Row CT and Electron-beam CT. *Radiology* 2003; 226(1): 145-52.
7. Gerber TC, Stratmann BP, Kuzo RS, et al. Effect of Acquisition Technique on Radiation Dose and Image Quality in Multidetector Row Computed Tomography Coronary Angiography with Submillimeter Collimation. *Invest Radiol* 2005; 40(8): 556-63.
8. Morin RL, Gerber TC, McCollough CH, Radiation Dose in Computed Tomography of the heart. *Circulation* 2003; 107(6): 917-22.
9. Berman DS, Hachamovitch R, Kiat H, et al. Incremental Value of Prognostic Testing in Patients with Known or Suspected Coronary Artery Disease: A Basis for Optimal Utilization of Exercise Myocardial Perfusion Single Photon Emission Computed Tomography. *J Am Coll Cardiol* 1995; 26: 639-47.
10. Paul AK, Nabi HA. Gated Myocardial Perfusion SPECT: Basic Principles, Technical Aspects and Clinical Applications. *J Nucl Med Technol* 2004; 32(4): 179-87.
11. Groch MW, Erwin WD. Single-photon Emission Computed Tomography in the Year 2001: Instrumentation and Quality Control. *J Nucl Med Technol* 2001; 29(1): 12-8.
12. Nichols K, Dorbala S, DePuey EG, et al. Influence of Arrhythmias on Gated SPECT Myocardial Perfusion and Function Quantification. *J Nucl Med* 1999; 40(6): 924-34.
13. Heller GV, Links J, Bateman TM, et al. American Society of Nuclear Cardiology / Society of Nuclear Medicine Joint Position Statement: Attenuation Correction of Myocardial Perfusion SPECT Scintigraphy. *J Nucl Cardiol* 2004; 11: 229-30.

14. Grossman GB, Garcia EV, Bateman TM, et al. Quantitative TC-99m Sestamibi Attenuation-Corrected SPECT: Development and Multicenter Trial Validation of Myocardial Perfusion Stress Gender-Independent Normal Database in an Obese Population. *J Nucl Cardiol* 2004; 11: 263-72.
15. Corbett JR, Ficaro EP. Clinical Review of Attenuation-Correction Cardiac SPECT. *J Nucl Cardiol* 1999; 6(1 Pt 1):54-68. Review.
16. Miles J, Cullom SJ, Case JA. An Introduction to Attenuation Correction. *J Nucl Cardiol* 1999; 6(4): 449-57.
17. Campeau RJ, Garcia OM, Colon R, et al. False Positive Tc-99m Sestamibi SPECT in a Patient with Left Bundle Branch Block. *Clin Nucl Med* 1993; 18(1): 40-2.
18. DePuey EG, Rozanski A. Using Gated Technetium-99m-Sestamibi SPECT to Characterize Fixed Myocardial Defects as Infarct or Artifact. *J Nucl Med* 1995; 36(6):952-5.
19. Slomka PJ, Nishina H, Berman DS, et al. Automated quantification of Myocardial Perfusion SPECT Using Simplified Normal Limits. *J Nucl Cardiol* 2005; 12(1): 66-77.
20. Van Train KF, Garcia EV, Maddahi J, et al. Multicenter Trial Validation for Quantitative Analysis of Same-day Rest-stress Technetium-99m-sestamibi Myocardial Tomograms. *J Nucl Med* 1994; 35(4): 609-18.
21. Hayes SW, De Lorenzo A, Hachamovitch R, et al. Prognostic Implications of Combined Prone and Supine Acquisitions in Patients with Equivocal or Abnormal Supine Myocardial Perfusion SPECT. *J Nucl Med* 2003; 44(10): 1633-40.