

Eruptive Syringoma

Manal Alsabbagh, MB BCh BAO* Mazen Raees, MB BCh BAO,
LRCP & SI (NUI), FACHARZT**

Syringoma is a benign neoplasm of eccrine glands. It is usually seen on the face in adult females with their recognized appearance: small flesh colored papules. As the condition is benign, the treatment is usually cosmetic.

The eruptive form of syringoma is one of the uncommon clinical presentations. We are reporting a case of a 29-year-old healthy male with progressive eruptive syringoma.

Bahrain Med Bull 2014; 36(1):

The word syringoma is derived from the Greek word syrinx meaning pipe or tube¹. Syringomas are common benign neoplasms of the eccrine glands. It usually affects adult females with its usual presentation; small smooth flesh-colored or yellowish papules with flattened or rounded tops on the face, especially the eyelids².

Eruptive syringoma has been described first by Jacquet and Darier as a rare variant of syringoma that presents with successive crops on the anterior trunk and axillae during childhood or at puberty³. Since its description, few cases have been reported⁴. According to Hassan S, et al, less than 100 cases have been reported⁵.

Friedman and Butler have classified syringoma into four variants: localized, lesions associated with Down's syndrome, generalized eruptive syringoma and a familial autosomal dominant form^{1,6}.

The aim of this presentation is to report a case of eruptive form of syringoma which was stable in the last 7 years and started to spread during last year.

* Senior House Officer

** Consultant Dermatologist & Venereologist
Internal Medicine Department- Dermatology
King Hamad University Hospital
Email: manal.alsabbagh@khuh.org.bh

THE CASE

A twenty-nine-year-old Arabian healthy gentleman presented with 8-year history of progressive papular rash.

The rash started on the upper chest and was stable for the last 7 years. In summers and humid weather, he would experience mild pruritus. Last year, it had spread to the abdomen and shoulders with the same features.

The patient had biopsy at the time it started; he was told that those lesions might spread to the face with a provisional diagnosis of syringoma.

The patient was a healthy man with no other skin complaints and negative family history of any skin diseases.

Examination revealed symmetrical, widely distributed, flesh-colored papules, some were erythematous, others were brown, 2-3 mm in size on the anterior aspect of the trunk and few over the shoulders, see figure 1.

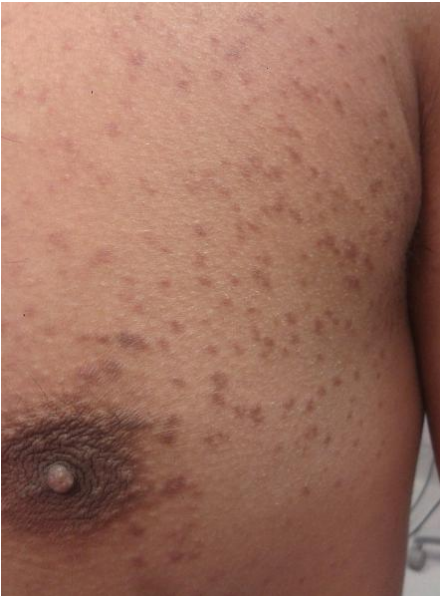

Figure 1: Numerous Skin Colored and Erythematous Papules on the Chest

In the beginning, our diagnosis was syringoma versus granuloma annulare. Punch biopsy was taken from a lesion in the abdomen and the result was confirmed to syringoma, see figure 2.

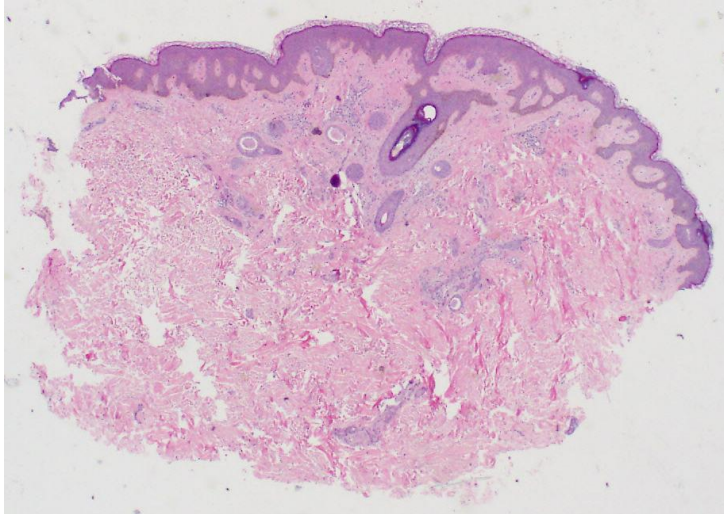


Figure 2: The Common 'Tadpole' Appearance of Ducts in the Dermis

Because this condition is benign, treatment modalities were discussed with the patient including the 'poor' cosmetic outcome and the risk of recurrence. He preferred to have no intervention. We advised him to avoid hot environment as much as possible and he was given an open appointment in dermatology department.

DISCUSSION

Although syringoma is a common benign tumor of the eccrine glands, the eruptive form is a rare variant that would usually present with widespread papular lesions over the trunk and limbs.

The eruptive form has been associated with Diabetes mellitus, Down's syndrome, sarcoidosis and psychiatric disorders^{7,8}. In addition, few cases have been reported in association with anti-epileptic medications, specifically Carbamazepine⁹. There are few cases of eruptive syringoma in children, some were associated with milia¹⁰.

The diagnosis of eruptive syringoma is usually histological. Besides its well-recognized histological appearance of the comma-shaped or tadpole shaped tubular structures in the superficial dermis, immunohistochemical tests may be performed to show the presence of enzymes related to eccrine glands such as leucine aminopeptidase, succinic dehydrogenase and phosphorylase⁶.

It has been suggested by researchers that eruptive syringoma is a hyperplastic reaction of the eccrine ducts secondary to inflammatory process and they have proposed the term "syringomatous dermatitis"^{11,12}.

The majority of the reported cases received no treatment because it is cosmetic. In addition, the treatment is associated with scarring and recurrence^{4,5}.

Treatment options vary between excision, dermabrasion, trichloroacetic acid, cryotherapy and electrosurgery. However, carbon dioxide laser therapy is promising¹³.

Our case is one of the few cases reported, presenting with eruptive syringoma in male patients and not associated with medications¹⁴. Most of the cases reported in male patients were familial, in pediatric age group, post-waxing, in association with medications or mainly in genital area^{9,11,15-18}.

CONCLUSION

A case of a 29-year-old healthy male suffering from progressive eruptive syringoma was reported.

Eruptive syringoma is a rare condition. Further research is needed to probe its etiology, associations and treatment options.

Author contribution: All authors share equal effort contribution towards (1) substantial contributions to conception and design, acquisition, analysis and interpretation of data; (2) drafting the article and revising it critically for important intellectual content; and (3) final approval of the manuscript version to be published. Yes.

Potential conflicts of interest: None.

Competing interest: None. **Sponsorship:** None.

Submission date: 27 October 2013 **Acceptance date:** 23 January 2014

Ethical approval: Research and Ethical committee, King Hamad University Hospital.

REFERENCES

1. Haubrich W. Medical Meaning: A Glossary of Word Origins. USA: American College of Physicians, 2003: 233.
2. James W, Berger T and Elston D. Andrews' Diseases of the Skin: Clinical Dermatology. 11th ed. USA: Saunders, 2011: 653-4.
3. Srivastava D, Taylor R. Appendage Tumors and Hamartomas of the Skin. In: Goldsmith L, Katz S, Gilchrest B, et al. Fitzpatrick's Dermatology in General Medicine. 8th ed. USA: McGraw Hill, 2012: 1348-9.
4. Soler-Carrillo J, Estrach T, Mascaró JM. Eruptive Syringoma: 27 New Cases and Review of the Literature. J Eur Acad Dermatol Venereol 2001; 15(3):242-6.
5. Hassan S, Rizvi N, Bhengra M, et al. Generalized Eruptive Syringoma. J Pak Assoc Derma 2012; 22: 153-6.

6. Christopher R. Syringoma. Available at: <http://emedicine.medscape.com/article/1059871-overview>. Accessed in August 2013.
7. Urban CD, Cannon JR, Cole RD. Eruptive Syringomas in Down's Syndrome. *Arch Dermatol* 1981; 117(6):374-5.
8. Daneshpazhooh M, Nazemi TM, Bigdeloo L, et al. Mucocutaneous Findings in 100 Children with Down Syndrome. *Pediatr Dermatol* 2007; 24(3):317-20.
9. Korekawa A, Nakajima K, Nishikawa Y, et al. Late-Onset, Eruptive Syringoma in an Elderly Man: Correlation with Carbamazepine. *Acta Derm Venereol* 2012; 92(1):87-8.
10. Sacoor MF, Medley P. Eruptive Syringoma in Four Black South African Children. *Clin Exp Dermatol* 2004; 29(6): 686-7.
11. Garrido-Ruiz MC, Enguita AB, Navas R, et al. Eruptive Syringoma Developed Over a Waxing Skin Area. *Am J Dermatopathol* 2008; 30:377-80.
12. Guitar J, Rosenbaum MM, Requena L. 'Eruptive syringoma': A Misnomer for a Reactive Eccrine Gland Ductal Proliferation? *J Cutan Pathol* 2003; 30(3):202-5.
13. Cho SB, Kim HJ, Noh S, et al. Treatment of Syringoma Using an Ablative 10,600-Nm Carbon Dioxide Fractional Laser: A Prospective Analysis of 35 Patients. *Dermatol Surg* 2011; 37(4):433-8.
14. Tsunemi Y, Ihn H, Saeki H, et al. Generalized Eruptive Syringoma. *Pediatr Dermatol* 2005; 22(5):492-3.
15. Lau J, Haber RM. Familial Eruptive Syringomas: Case Report and Review of the Literature. *J Cutan Med Surg* 2013; 17(2):84-8.
16. Akaraphanth R, Giam YC. Eruptive Syringoma in a Chinese Boy. *Int J Dermatol* 1993; 32(3):202-3.
17. Olson JM, Robles DT, Argenyi ZB, et al. Multiple Penile Syringomas. *J Am Acad Dermatol* 2008; 59(2 Suppl 1):S46-7.
18. Cohen PR, Tschen JA, Rapini RP. Penile Syringoma: Reports and Review of Patients with Syringoma Located on the Penis. *J Clin Aesthet Dermatol* 2013; 6(6):38-42.