

## Medical Quiz

Najeeb S Jamsheer, MD\*

Neelam Malik, MD\*\*

A 48 year old Bahraini female was referred for abdominal ultrasound examination with the clinical diagnosis of Systemic Lupus Erythematosus (SLE) for the evaluation of the kidneys. The patient had no flank pain or haematuria. No other clinical or laboratory signs of renal involvement by SLE were present.

Based on the ultrasound finding, computed tomography (CT) of abdomen was performed.

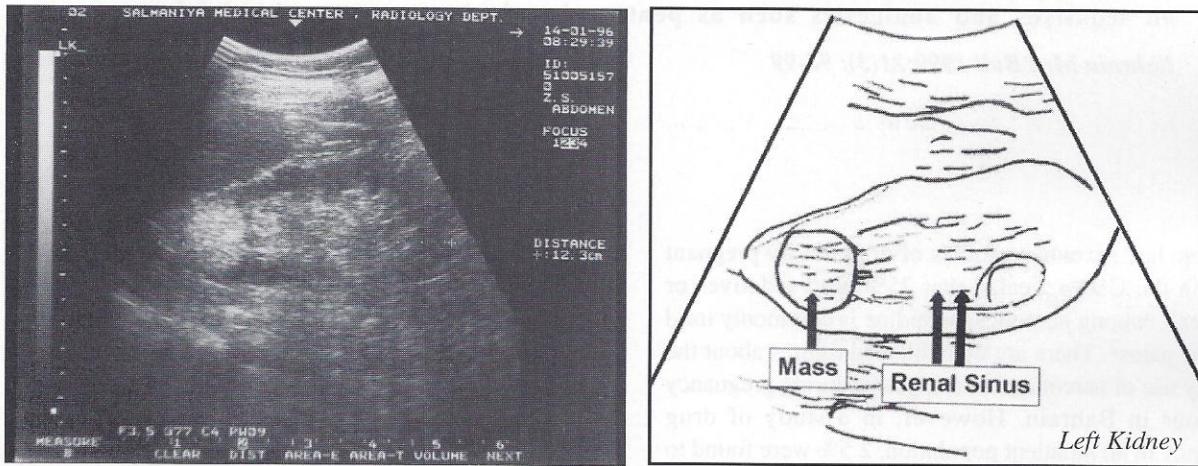


Figure 1.

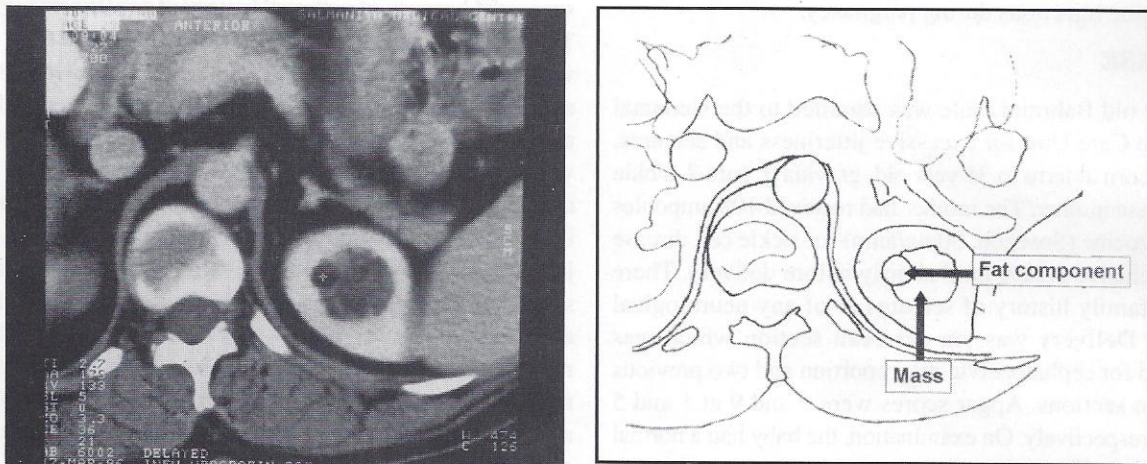


Figure 2.

Q1. Describe the renal ultrasound ( Fig.1 ) and CT scan ( Fig.2 ) findings.

Q2. What is your diagnosis ?

Answers on page ...106