

Seven Year Old Boy with Abnormal Behavior - Methylmalonic Aciduria and Homocystinuria

Raafat Hammad Seroor Jadah, MD*

Mutations in the methylmalonic aciduria and homocystinuria type c.394C> T (p.R 132X) can cause a defect in B₁₂ metabolism, which could lead to neuropsychiatric disorder.

We report a seven year old boy with abnormal behavior. Brain MRI showed T2 and FLAIR hyperintensities in the cerebral white matter.

The patient methylmalonic aciduria and homocystinuria type c gene was positive for c.394C> T (p.R 132X). The clinical symptoms improved after Cobalamin replacement therapy.

Bahrain Med Bull 2012; 34(3):

Methylmalonic aciduria and homocystinuria cbIC type is the most common inborn error of Vitamin B₁₂ (Cobalamin, cbI) metabolism^{1,2}.

The most common is c.271 dupA (P.R 91KfsX 14), which accounts for 40% of mutations and has been associated with early onset of the disease². On the other hand, the missense mutation c.394C> T (p.R 132X) has been related to late onset of the disease³.

Treatment of methylmalonic aciduria and homocystinuria cbIC type with hydroxocobalamin may ameliorate the clinical features of early-onset disease and prevent clinical late-onset of the disease.

The aim of this report is to present a rare case of Methylmalonic aciduria and homocystinuria cbIC type.

THE CASE

Seven year old boy previously healthy presented with change of behavior of three weeks duration: slurring of speech, irritability, agitation and screaming, increased hours of sleep, urinary incontinence, poor interest in surroundings, deficiency in school performance and decreased overall activity. History revealed febrile illness one month ago.

The family also reported two episodes of abnormal movement in the form of upward eyes staring with impairment of consciousness followed by drowsiness.

* Senior Resident
Pediatric Department
BDF Hospital Bahrain
E-mail: nader212@hotmail.com

There was no history of headache, vomiting, diarrhea, trauma, drugs ingestion or skin rash. Previously he had good performance at school. The family history was not remarkable.

Physical examination showed normal vital signs. Weight and height was >90th percentile. Glasgow coma scale was 15/15. He is fully awake but not interested in his surroundings and has slurred speech. No skin rash or neuro-cutaneous stigmata were seen. He had intact cranial nerves, normal tone, power and reflexes, no cerebellar signs and had slow higher mental functions. He could not remember words after 5 minutes, draw triangle, identified letters and write his name.

Hematological, biochemical and cerebrospinal fluid investigation results were within normal. All cultures were negative.

EEG showed slowing of the background with left parietotemporal sharp waves discharges. MRI Brain showed T2 and FLAIR hyperintensities in the cerebral white matter, see figures 1 (a, b) and 2 (a, b).

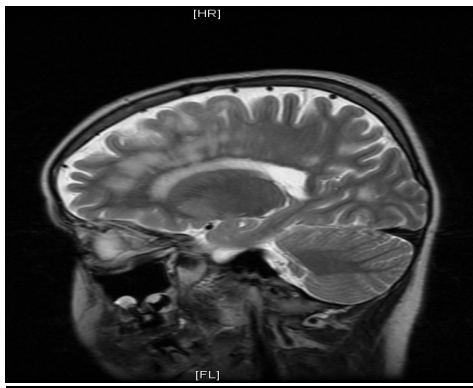


Figure 1 (a): MRI of the Brain T2 Sequence Sagittal View Showing Hyperintensities in the Cerebral White Matter

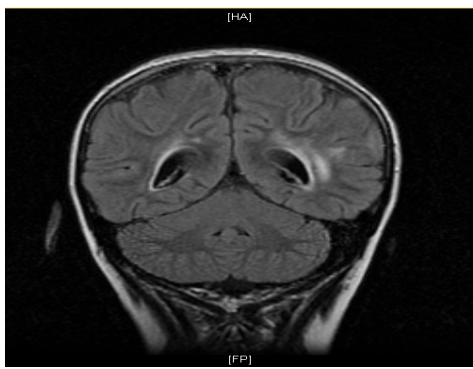


Figure 1 (b): MRI of the Brain FLAIR Sequence Coronal View Showing Hyperintensities in the Cerebral White Matter

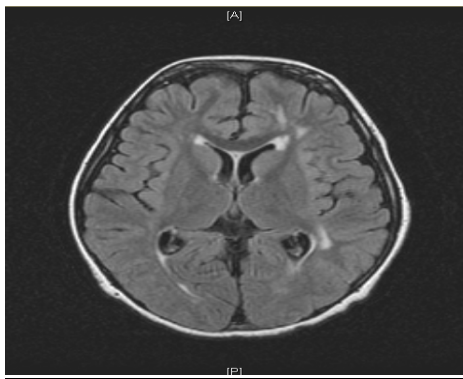


Figure 2 (a): MRI of the Brain FLAIR Sequence Axial View Showing Hyperintensities in the Cerebral White Matter

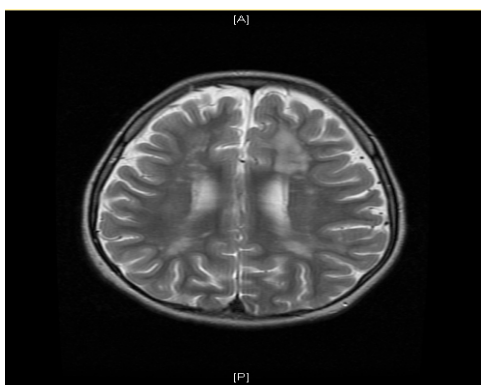


Figure 2 (b): MRI of the Brain T2 Sequence Axial View Showing Hyperintensities in the Cerebral White Matter

The patient initially started on pulse steroid for acute disseminated encephalomyelitis with no improvement. Further laboratory tests were performed for white matter disease, which showed normal level of arylsulfatase A, galactocerebrosidase and very long chain fatty acid. Vitamin B₁₂ level was 531 pmol/L (Normal range: 139-651 pmol/L). Urine methylmalonic acid was high (104 mmol/L) (Normal range: < 1 mmol/L). Blood methylmalonic acid was 19.5 mmol/L (Normal range: < 0.5 mmol/L). Homocystine level was 80 mmol/L (Normal range: 6-16 mmol/L).

The patient's methylmalonic aciduria and homocystinuria cbIC type gene was positive for c.394C>T (p.R 132X) mutation. The patient started on course of Cyanocobalamin (Vitamin B₁₂) IM with good response and recovery of the neuropsychiatric symptoms.

DISCUSSION

Methylmalonic aciduria and homocystinuria, cbIC type is the most common inborn error of Vitamin B₁₂ (Cobalamin, Cbl) metabolism^{1,2}.

It is an autosomal recessive disorder³. The MMACHC (Methylmalonic aciduria and homocystinuria type C) gene responsible for cbIC disorder is located on chromosome 1p34.1⁴.

A defect in the Cobalamin C (cbIC) causes impairment in the metabolism of Vitamin B₁₂ into its two active forms Methylcobalamin and Adenosylcobalamin which leads to accumulation of methylmalonic acid, homocystine and decrease methionine synthesis⁵.

The most common MMACHC gene is the c.271 dupA (P.R 91KfsX14), which account for 40% of alleles mutations and has been associated with early onset of the disease, which include developmental regression, cortical atrophy, hypotonia, seizure, microcephaly and optic atrophy^{2,6}.

Patient with c.394C> T (p.R 132X) mutation shows late onset disease in childhood or adolescence, which include myelopathy, decrease cognitive performance, behavioral and neuropsychiatric disturbances^{3,7}.

Brain MRI might show T2 and FLAIR hyperintensities in the cerebral white matter in patients with Vitamin B₁₂ deficiency^{8,9}.

Clinically, patients with c.394C> T (p.R 132X) mutation often respond to Vitamin B₁₂ replacement therapy with recovery of neuropsychiatric manifestations^{1,10,11}.

CONCLUSION

Methylmalonic aciduria and homocystinuria cbIC type is a treatable disease; early diagnosis would be better outcome.

A patient with methylmalonic aciduria and homocystinuria type c Gene was presented and treated with Cyanocobalamin and had a favorable outcome.

Potential conflicts of interest: No

Competing interest: None **Sponsorship:** None

Submission date: 4 May 2012 **Acceptance date:** 7 June 2012

Ethical approval: Approved by Pediatric Department, BDF Hospital.

REFERENCES

1. Thauvin-Robinet C, Roze E, Couvreur G, et al. The Adolescent and Adult form Cobalamin C Disease: Clinical and Molecular Spectrum. *J Neurol Neurosurg Psychiatry* 2008; 79(6): 725-8.
2. Lerner-Ellis JP, Tirone JC, Pawelek PD, et al. Identification of the Gene Responsible for Methylmalonic Aciduria and Homocystinuria, cbIC Type. *Nature Genetic* 2006; 38(1): 93-100.

3. Ben-Omran TI, Wong H, Blaser S, et al. Late Onset Cobalamin-C Disorder: A Challenging Diagnosis. *Am J Med Genet A* 2007; 143 A(9): 979-84.
4. Chang JT, Chen YY, Liu TT, et al. Combined Methylmalonic Aciduria and Homocystinuria cbIC Type of a Taiwanese Infant with c. 609 G > A and c. 567 DupT Mutations in the MMACHC Gene. *Pediatr and Neonatol* 2011; 52(4): 223-6.
5. Carrillo-Carrasco N, Chandler RJ, Venditti CP, et al. Combined Methylmalonic Acidemia and Homocystinuria, cbIC Type I. Clinical Presentation, Diagnosis and Management. *J Inherit Metab Dis* 2012; 35(1): 91-102.
6. Casella EB, Valente M, de Navarro JM, et al. Vitamin B₁₂ Deficiency in Infancy as a Cause of Developmental Regression. *Brain Dev* 2005; 27(8): 592-4.
7. Tsai HC, Morel CF, Scharer G, et al. Late - Onset Combined Homocystinuria and Methylmalonic Aciduria (cbIC) and Neuropsychiatric Disturbances. *Am J Med Genet* 2007; 143A(20): 2430-4.
8. Kalita J, Misra UK. Vitamin B₁₂ Deficiency Neurological Syndromes: Correlation of Clinical, MRI and Cognitive Evoked Potential. *J Neurol* 2008; 255(3): 353-9.
9. Stojavljevic N, Levic Z, Drulovic J, et al. A 44-Month Clinical-Brain MRI Follow-up in a Patient with B₁₂ Deficiency. *Neurology* 1997; 49(3): 878-81.
10. Kamei M, Ito Y, Ando N, et al. Brain Atrophy Caused by Vitamin B₁₂-Deficient Anemia in an Infant. *J Paediatr Hematol Oncol* 2011; 33(7): 556-8.
11. Aaron S, Kumar S, Vijayan J, et al. Clinical and Laboratory Features and Response to Treatment in Patients Presenting with Vitamin B₁₂ Deficiency-Related Neurological Syndromes. *Neurol India* 2005; 53(1): 55-8.